





Congenital Extrahepatic Portosystemic Shunts (Abernethy Malformation): An International Observational Study

Anna Baiges,¹ Fanny Turon,¹ Macarena Simón-Talero,² Stephanie Tasayco,² Javier Bueno,³ Kamal Zekrini,⁴ Aurélie Plessier,⁴ Stéphanie Franchi-Abella,⁵ Florent Guerin,⁵ Amar Mukund,⁶ C.E. Eapen,⁷ Ashish Goel,⁷ Nidugala Keshava Shyamkumar,⁸ Sandra Coenen,⁹ Andrea De Gottardi,¹⁰ Avik Majumdar,¹¹ Simona Onali,¹¹ Akash Shukla,¹² Flair José Carrilho,¹³ Lucas Nacif,¹³ Massimo Primignani,¹⁴ Giulia Tosetti,¹⁴ Vincenzo La Mura,^{14,15} Frederik Nevens,¹⁶ Peter Witters,¹⁶ Dhiraj Tripathi,¹⁷ Luis Tellez,¹⁸ Javier Martínez,¹⁸ Carmen Álvarez-Navascués,¹⁹ Miguel López Fraile López ,¹⁹ Bogdan Procopet,²⁰ Fabio Piscaglia,²¹ Barbara de Koning,²² Elba Llop,²³ Mario Romero-Cristobal,²⁴ Eric Tjwa,²⁵ Alberto Monescillo-Francia,²⁶ Marco Senzolo,²⁷ Mercedes Perez-LaFuente,²⁸ Antonio Segarra,²⁸ Shiv Kumar Sarin ,²⁹ Virginia Hernández-Gea,¹ David Patch,¹¹ Wim Laleman,¹⁵ Hermien Hartog,⁹ Dominique Valla,⁴ Joan Genescà ,² and Juan Carlos García-Pagán ¹; for the REHEVASC, VALDIG an EASL consortium, Abernethy group*

Congenital extrahepatic portosystemic shunt (CEPS) or Abernethy malformation is a rare condition in which splanchnic venous blood bypasses the liver draining directly into systemic circulation through a congenital shunt. Patients may develop hepatic encephalopathy (HE), pulmonary hypertension (PaHT), or liver tumors, among other complications. However, the actual incidence of such complications is unknown, mainly because of the lack of a protocolized approach to these patients. This study characterizes the clinical manifestations and outcome of a large cohort of CEPS patients with the aim of proposing a guide for their management. This is an observational, multicenter, international study. Sixty-six patients were included; median age at the end of follow-up was 30 years. Nineteen patients (28%) presented HE. Ten-, 20-, and 30-year HE incidence rates were 13%, 24%, and 28%, respectively. No clinical factors predicted HE. Twenty-five patients had benign nodular lesions. Ten patients developed adenomas (median age, 18 years), and another 8 developed HCC (median age, 39 years). Of 10 patients with dyspnea, PaHT was diagnosed in 8 and hepatopulmonary syndrome in 2. Pulmonary complications were only screened for in 19 asymptomatic patients, and PaHT was identified in 2. Six patients underwent liver transplantation for hepatocellular carcinoma or adenoma. Shunt closure was performed in 15 patients with improvement/stability/cure of CEPS manifestations. *Conclusion:* CEPS patients may develop severe complications. Screening for asymptomatic complications and close surveillance is needed. Shunt closure should be considered both as a therapeutic and prophylactic approach. (HEPATOLOGY 2020;71:658-669).

Congenital extrahepatic portosystemic shunts (CEPS) is a rare condition in which most of the intestinal and splenic venous blood bypasses the portal vein and the liver, draining directly into systemic veins through abnormal communications. Anatomically, CEPS has been

Abbreviations: AFP, alpha-fetoprotein; CEPS, congenital extrahepatic portosystemic shunt; CT, computed tomography; GP, globus pallidum; HCC, hepatocellular carcinoma; HE, hepatic encephalopathy; HPS, hepatopulmonary syndrome; IVC, inferior vena cava; IPSS, intrahepatic portosystemic shunt; LT, liver transplantation; MRI, magnetic resonance imaging; PaHT, pulmonary arterial hypertension.

Received December 4, 2018; accepted May 21, 2019.

Additional Supporting Information may be found at onlinelibrary.wiley.com/doi/10.1002/hep.30817/supinfo.

Supported by the Ministry of Education and Science (SAF-2016-75767-R), and Instituto de Salud Carlos III (PIE15/00027), FEDER “Una manera de hacer Europa”. The Centro de Investigación Biomédica en Red de Enfermedades Hepáticas y Digestivas (CIBERehd) is funded by the Instituto de Salud Carlos III. IDIBAPS CERCA Programme/Generalitat de Catalunya, Societat Catalana de Digestologia. REHEVASC is partially funded by Asociación Española para Estudio del Hígado (AEEH). VALDIG is supported by a grant from the European Association for the Study of the Liver (EASL). Macarena Simón-Talero is a recipient of a Juan Rodés grant (JR17/00029) from Instituto de Salud Carlos III, Spain. Stephanie Tasayco is a recipient of a PFIS grant (FI16/00238) from Instituto de Salud Carlos III, Spain. Joan Genescà is supported by Instituto de Salud Carlos III, Spain (Research Intensification grant, PI15/00066 and PI18/00947) and by the European Union (ERDF/ESF, “Investing in your future”).

classified in two types.^(1,2) Type 1 CEPS is characterized by the absence of intrahepatic portal vein branches and an end-to-side portocaval shunt, whereas in type 2 CEPS the intrahepatic veins are hypoplastic but patent and a side-to-side shunt diverts blood from the portal vein to the inferior vena cava (IVC). Type 1 CEPS can be further classified into type 1a, when the superior mesenteric and splenic vein drain separately into the IVC, and

type 1b when these veins form a common trunk before draining into the IVC.

Recently, more detailed anatomical subclassifications^(3,4) have been described, correlating the anatomy of the shunt to the surgical approach required for its closure.^(4,5) It has also been stated that to accurately assess the patency of intrahepatic veins, an angiography with occlusion of the shunt should be performed, to distinguish whether the assumed absence

**Members of the Abernethy group are listed in the Appendix.*

© 2019 by the American Association for the Study of Liver Diseases.

View this article online at wileyonlinelibrary.com.

DOI 10.1002/hep.30817

Potential conflict of interest: Dr. Alvarez-Navascues consults for and is on the speakers' bureau for AbbVie. She is on the speakers' bureau for Gilead. Dr. Piscaglia advises for and is on the speakers' bureau for Bayer, Eisai, and AstraZeneca. He consults for GE and Tiziana. He is on the speakers' bureau for Bracco, Bristol-Myers Squibb, and LaForce/Guerbet. He received grants from Esaote and Siemens.

ARTICLE INFORMATION:

From the ¹Barcelona Hepatic Hemodynamic Laboratory, Liver Unit, Hospital Clínic de Barcelona, IDIBAPS, CIBERehd, Universitat de Barcelona, Barcelona, Spain; ²Liver Unit, Department of Internal Medicine, Hospital Universitari Vall d'Hebrón, VHIR, CIBERehd, Universitat Autònoma de Barcelona, Barcelona, Spain; ³Pediatric Surgery Department, Hospital Universitari Vall d'Hebrón, Universitat Autònoma de Barcelona, Barcelona, Spain; ⁴DHU Unity, Pôle des Maladies de l'Appareil Digestif, Service d'Hépatologie, Centre de Référence des Maladies Vasculaires du Foie, Hôpital Beaujon, AP-HP, Clichy, France; ⁵Service d'Hépatologie et de Transplantation Hépatique et de radiologie Pédiatriques, Groupement Hospitalier Paris Sud (GHUPS), Hôpital Bicêtre, Le Kremlin Bicêtre, France; ⁶Department of Radiology, Institute of Liver and Biliary Sciences, New Delhi, India; ⁷Hepatology Department, Christian Medical College, Vellore, India; ⁸Department of Radiology, Christian Medical College, Vellore, India; ⁹Department of Gastroenterology and Hepatology, Erasmus Medical Center, Rotterdam, The Netherlands; ¹⁰Hepatology, Clinic of Visceral Surgery and Medicine, Inselspital and Department of Clinical Research, University of Bern, Bern, Switzerland; ¹¹Sheila Sherlock Liver Unit and UCL Institute for Liver and Digestive Health, Royal Free Hospital and UCL, London, United Kingdom; ¹²Department of Gastroenterology, Seth G S Medical College & KEM Hospital, Mumbai, Maharashtra, India; ¹³Digestive Organ Transplantation Division, Department of Gastroenterology, Faculty of Medicine, University of São Paulo, São Paulo, Brazil; ¹⁴A. M. e A. Migliavacca Center for Liver Disease, Division of Gastroenterology and Hepatology, Fondazione IRCCS Ca' Granda Ospedale Maggiore Policlinico, University of Milan, Milan, Italy; ¹⁵Fondazione IRCCS Ca' Granda, Ospedale Maggiore Policlinico, UOC Medicina Generale Emostasi e Trombosi, Milano, Italy; ¹⁶Department of Gastroenterology and Hepatology, University Hospitals Leuven, KU Leuven, Leuven, Belgium; ¹⁷Liver Unit, Queen Elizabeth Hospital, Birmingham, United Kingdom; ¹⁸Department of Gastroenterology and Hepatology, Hospital Universitario Ramón y Cajal, IRYCIS, University of Alcalá, CIBERehd, Madrid, Spain; ¹⁹Aparato Digestivo, Hospital Universitario Central de Asturias HUCA, Asturias, España; ²⁰Department of Gastroenterology, 3rd Medical Clinic, University of Medicine and Pharmacy "Iuliu Hatieganu", Regional Institute of Gastroenterology and Hepatology "O Fodor", Cluj-Napoca, Romania; ²¹Unit of Internal Medicine, Department of Medical and Surgical Sciences, University of Bologna, S. Orsola-Malpighi Hospital, Bologna, Italy; ²²Division of Pediatric Gastroenterology, Erasmus MC-Sophia Children's Hospital, Rotterdam, The Netherlands; ²³Liver Unit, Hospital U. Puerta de Hierro, Universidad Autónoma de Madrid, Madrid, Spain; ²⁴Digestive Diseases and Centro de Investigación Biomédica en Red de Enfermedades Hepáticas y Digestivas Hospital General Universitario Gregorio Marañón Instituto de Investigación Sanitaria Gregorio Marañón Facultad de Medicina, Universidad Complutense, Madrid, Spain; ²⁵Department of Gastroenterology and Hepatology, Radboud University Medical Centre, Nijmegen, The Netherlands; ²⁶Digestive Disease Department, Complejo Hospitalario Universitario Insular-Materno Infantil, Las Palmas de Gran Canaria, España; ²⁷Multivisceral Transplant Unit, Department of Surgery, Oncology and Gastroenterology, Padua University Hospital, Padua, Italy; ²⁸Interventional Radiology Unit, Hospital Universitari Vall d'Hebrón, Universitat Autònoma de Barcelona, Barcelona, Spain; ²⁹Department of Hepatology, Institute of Liver and Biliary Sciences, New Delhi, India.

ADDRESS CORRESPONDENCE AND REPRINT REQUESTS TO:

Juan Carlos García-Pagán, M.D., Ph.D.
Barcelona Hepatic Hemodynamic Laboratory
Liver Unit, Hospital Clínic
Villarroel 170

Barcelona 08036, Spain
E-mail address: jcgarcia@clinic.cat
Tel.: +34 93 227 57 39

of intrahepatic veins could, in fact, be concealing remnant hypoplastic hepatic branches.^(3,4,6)

CEPS is usually associated with congenital anomalies, the most frequent being cardiac abnormalities, genitourinary malformations, and musculoskeletal defects. Biliary atresia has also been associated with CEPS.^(2,7-9)

In countries routinely performing neonatal screening for hereditary galactosemia, it has been estimated that incidence of congenital portosystemic shunts is around 1 in 30,000 births^(10,11) (high levels of galactose can be found in newborns with congenital portosystemic shunts because galactose bypasses the liver). However, the usefulness of galactosemia screening to infer CEPS prevalence is debatable because other circumstances could cause false-positive results, galactosemia levels cannot differentiate intra- and extrahepatic shunts, and, finally, it may underestimate its real prevalence given that not all patients with CEPS harbor hypergalactosemia.

To our knowledge, less than 300 cases of CEPS have been reported in the literature. The spectrum of clinical variants of CEPS ranges from completely asymptomatic forms to severe forms of hepatic encephalopathy (HE),^(12,13) hepatopulmonary syndrome (HPS), and pulmonary arterial hypertension (PaHT).⁽¹⁴⁻¹⁶⁾ Nodular liver lesions are frequent in patients with CEPS and although most of these nodules are benign, hepatocellular carcinomas (HCCs) and adenomas, among other neoplastic lesions, have been reported.^(17,18) However, the vast majority of these publications are single case reports providing only a cross-sectional description without follow-up. Although some series have been reported,^(3,4,19,20) most mix patients with CEPS and intrahepatic congenital portosystemic shunts (IPSS). The natural history of these two entities might be different, with IPSS more frequently asymptomatic and undergoing spontaneous closure during infancy (<2 years old). Moreover, there are no reports of malignant liver tumors in IPSS.^(13,21) For these reasons, our study focuses on extrahepatic shunts only.

Because knowledge on the natural history and outcome of patients with Abernethy malformation are mainly based on pediatric series, there are no formal recommendations on the evaluation and management of adult patients with CEPS. Our study describes the clinical manifestations, natural history, current diagnostic procedures, treatments applied, and outcome of a large cohort of patients with CEPS with the aim of proposing a guide to homogeneously approach these patients.

Patients and Methods

This is a multicenter, observational, retrospective, international study performed in the setting of the VALDIG Group (Vascular Liver Disease Interest Group) and the REHEVASC group (Registro Español de Enfermedades Vasculares Hepáticas). The 23 participating hospitals are listed in Supporting Information Annex S1. The local ethical committees of each hospital approved the study in accord with the International Guideline for Ethical Review of Epidemiological Studies and principles of the Declaration of Helsinki.

PATIENTS AND STUDY DESIGN

Every patient diagnosed in any of the participating hospitals was considered for inclusion if they had at least one imaging study demonstrating the presence of CEPS.

Demographic, clinical, and imaging data at diagnosis were retrospectively recorded as well as follow-up data and the therapeutic approaches in a specifically designed case report form. HE, PaHT, HPS, HCC, and adenoma were considered major CEPS complications.

STATISTICAL ANALYSIS

Categorical variables are reported as absolute and relative frequencies (%) and continuous variables as mean \pm standard deviation or median and range. Groups were compared using the Chi-square and Fisher's exact test for categorical variables and the T test or Mann-Whitney U test for continuous variables. CEPS complications curves were performed with the Kaplan-Meier method. Differences have been considered statistically significant with *P* values <0.05. Statistical analyses have been performed by IBM SPSS Statistics 20.0 (IBM Corp., Armonk, NY).

Results

Since June 1989 until May 2018, 76 eligible patients were identified at the 23 participating centers. Ten of these patients were excluded from the study: 3 because CEPS diagnosis was not conclusive, 3 because they presented an IPSS instead of CEPS, and 4 because they had concomitant cirrhosis at diagnosis, making it difficult to establish whether symptoms were attributed

to cirrhosis or to CEPS. Finally, 66 patients with Abernethy malformation were included. Of those, 10 patients had been previously reported as isolated case reports or as part of small series.^(4,22-24) Follow-up of these patients has been updated for the current study. Of the 66 patients, 35 (53%) were men. At diagnosis, patients had a median age of 21 years (range, 0-66). Median follow-up was of 5.2 years (range, 0-22), and median age at the end of follow-up was 30 years (range, 0-68). Table 1 shows baseline characteristics of patients at diagnosis, and Supporting Fig. S1 shows the distribution of age at diagnosis. Table 2 summarizes the findings of the current study.

DIAGNOSIS

All patients were incidentally diagnosed through imaging tests. In 13 of the 66 patients (19.7%), the imaging test was performed because patients already presented with symptoms potentially attributable to

CEPS: HE in 6 cases and dyspnea in 7 cases. In the remaining 53 patients (80.3%), the imaging study was performed for other different reasons (Table 1).

There were no significant differences in age at diagnosis between patients with symptoms at diagnosis (22 years; range, 2-64) or without symptoms (24 years; range, 0-66; $P = 0.57$).

Imaging studies demonstrating the presence of CEPS were a Doppler ultrasound (US) in 3 patients (4.5%), computed tomography (CT) scan in 36 patients (54.5%), magnetic resonance imaging (MRI) in 10 patients (15.2%), and both CT and MRI in 17 patients (25.8%). Based on these imaging studies, type 1 CEPS was identified in 39 patients (59%; type 1a and type 1b in 7 and 32 patients, respectively) and type 2 in the remaining 27 patients (41%). There were no significant differences in sex, association to other congenital malformations, or age at diagnosis between type 1 and 2 CEPS. Remarkably, 8 patients classified as type 1 CEPS at CT scan were shown to actually have intrahepatic portal vein inflow when further studied with an endovascular shunt occlusion test. This occlusion test was not performed in all patients, making it impossible to rule out that other patients previously considered as type 1 had indeed type 2 CEPS with residual hypoplastic portal branches.

Although not necessary for diagnosis, in 19 patients (29%) a liver biopsy was performed. Liver biopsies were considered normal in 3 patients whereas the remaining 16 patients presented structural changes in different degrees: In 9 patients, there were absent or hypoplastic portal vein branches in the portal tracts, combined in some cases with congestive sinusoids and large arterial branches; 8 patients presented low degree of periportal fibrosis, and 3 patients presented moderate steatosis. Liver blood test at diagnosis showed a preserved liver function with a median albumin of 37.5 mg/dL (range, 30-46), prothrombin ratio of 80% (range, 60-100), and bilirubin of 1.1 mg/dL (range, 0.17-4.00).

ASSOCIATED CONGENITAL MALFORMATIONS

Twenty-nine patients (44%) presented one or multiple associated malformations (Supporting Table S1). Cardiac defects were the most common defects ($n = 20$), followed by musculoskeletal abnormalities ($n = 9$).

TABLE 1. Baseline Characteristics (n = 66)

	N	%
Sex (male)	35	53
Reason diagnosis		
CEPS symptoms:	13	19.7
HE	6	9.1
Dyspnea	7	10.6
Imaging study for:		
Abnormal liver test	16	24.2
Abdominal pain	10	15.2
Other malformations	7	10.6
Prenatal US	2	3
Others	18	27.3
Type 1 CEPS	39	59
Type 1a	7	
Type 2b	32	
Type 2 CEPS	27	41
	Median	Range (SD)
Age at diagnosis	21	0-66 (16.7)
ALT U/L	36	10-103 (21.1)
AST U/L	38	11-93 (17.9)
GGT U/L	79	15-370 (95.1)
Bilirubin mg/dL	1.1	0.1-4.0 (0.94)
Ammonia $\mu\text{mol/L}^*$	101	48-273 (49.7)
Prothrombin ratio	80	60-100 (13)

*Ammonia levels were determined in 20 patients. Abbreviations: ALT, alanine aminotransferase; AST, aspartate aminotransferase; GGT, gamma-glutamyl transferase.

TABLE 2. Main CEPS Complications

	Age at Complication (Median, Range)	Sex (Male)	Type 1 CEPS	Shunt Closure
HE: n = 19 (29%)	12 (5-65)	9 (47%)	12 (63%)	4
PaHT: n = 10 (15%)	20 (2-42)	6 (60%)	6 (60%)	3
HPS: n = 2 (3%)	41 (41-41)	1 (50%)	0	2
HCC: n = 8 (12%)	39 (32-53)	7 (87%)	8 (100%)	0
Adenoma: (n = 10, 15%)	18 (4-46)	0	7 (70%)	1
No main complications (n = 21, 32%)	30 (0-67)*	16 (76%)	13 (62%)	5

*Age at last follow-up.

HE

Nineteen patients (29%) developed HE at some time during the study. Median age at HE diagnosis was 12 years (range, 5-65). HE was already present at diagnosis in 14 patients whereas the other 5 patients developed HE during follow-up.

Different patterns of HE were observed with a clear preponderance of chronic HE: 14 patients had persistent HE with permanent cognitive impairment; 2 patients had recurrent HE; and 3 patients had episodic HE. In most patients, episodes of HE were of moderate intensity (grade I in 11 patients and grade II in 7 according to West-Haven criteria), and only 1 patient had grade III-IV HE. Presence of minimal HE was tested only in 2 asymptomatic patients with the critical flicker frequency test and psychometric hepatic encephalopathy score tests, and 1 patient was classified as having minimal HE.

Cumulative probability of HE at 10, 20, and 30 years was 13%, 24%, and 28% (Fig. 1A). Sixteen of the 19 patients with HE (84%) presented with HE before the age of 25 whereas the remaining 3 patients had HE after the age of 50. These 3 patients represent 27% of all patients with an age above 50. There were no significant differences in the incidence of HE between patients with type 1 or type 2 CEPS (Fig. 1B; $P = 0.57$). In addition, there were no significant associations between HE development and sex, presence of associated malformations, parameters assessing liver function, or presence of other CEPS manifestations.

Brain MRI was performed in 19 of the 66 patients (29%). In 10 patients, MRI was performed after developing HE and in 9 cases in the absence of previous HE (Supporting Table S2). Presence of high signal intensity in the globus pallidum (GP) on T_1 -weighted images was more frequent in patients with HE (70% vs. 30%; $P = 0.17$). Among the 3 patients without HE but

with GP high intensity at MRI, 1 patient developed HE 4 years later, whereas none of the 6 without neither HE nor GP high intensity presented clinical HE after a median follow-up of 20 years (range, 1.5-35.0). No relation was detected between grade or pattern of HE and the presence/absence of high GP intensity.

Venous serum ammonia levels determined in 20 patients at diagnosis were high in almost all patients (median, 89.5 $\mu\text{mol/L}$; range, 48-273; normal value, <50). Eight patients had already developed HE at the moment of the test, but no significant differences in serum ammonia levels were found with those of the remaining 12 patients who had not developed HE: 106 $\mu\text{mol/L}$ (range, 48-273) for HE versus 99 $\mu\text{mol/L}$ (range, 57-163) for no HE. Similarly, there was no relation between serum ammonia levels and other clinical characteristics of patients such as CEPS type, age at testing, sex, or brain MRI findings.

Thirteen patients had additional serum ammonia tests during follow-up (after liver transplantation [LT] in 1, shunt closure in 6, and after medical treatment of HE in 6), showing a significant reduction in levels in all but 1 patient (median ammonia levels, 51 $\mu\text{mol/L}$; range, 23-95).

LIVER NODULES

All patients were screened for nodules. In 43 of the 66 patients (65%), liver nodules were identified. Of the 43 patients with nodules, 9 patients (21%) had a single nodule, 24 patients (55%) had 2 to 10 nodules, 5 patients (12%) had 10 to 20 nodules, and 5 patients had more than 20.

The nature of liver nodules was established by biopsy in 25 patients (58%) and through imaging characterization in the remaining 18 patients. Supporting Table S3 shows liver nodules classification in patients with and without biopsy.

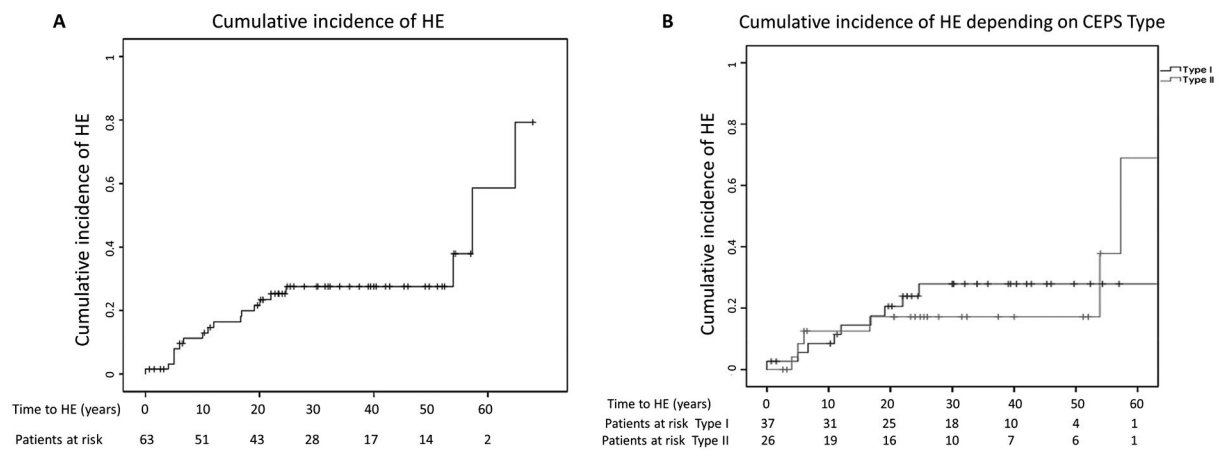


FIG. 1. (A) Cumulative incidence of HE. (B) Cumulative incidence of HE depending on CEPS type.

Overall, 18 patients had neoplastic lesions (8 HCC and 10 adenomas) and 25 patients had non-neoplastic nodules (nodular regenerative hyperplasia in 7, focal nodular hyperplasia in 12, and nonspecific in 6). HCC was diagnosed at a median age of 39 years (range, 32-53) and had a median size of 94 mm (range, 11-160); four of them were identified at CEPS diagnosis whereas the other four were identified after a median of 9 years of follow-up (range, 4-16). Adenomas were diagnosed at a median age of 18 years (range, 4-46) and had a median size of 76 mm (range, 11-180). Benign nodules were identified at a median age of 20 years (range, 7-52) and had a median size of 36 mm (range, 10-100).

Alpha-fetoprotein (AFP) levels were evaluated in 39 patients, including all patients with HCC. It was found that AFP was elevated only in 5 patients, 4 of whom presented HCC (median, 1,459.5 U/mL; range, 74-7,627). The remaining 4 patients with HCC had normal levels of AFP. The only patient with high AFP without HCC remained without evidence of HCC until the end of his follow-up 2 years later. All cases of HCC were identified in patients with type 1 CEPS (type 1, $n = 8$; type 2, $n = 0$; $P = 0.03$). Seven of the 8 patients with HCC were male ($P = 0.05$), corresponding to a cumulative incidence of HCC of 40% in males with type 1 CEPS older than 30 years. Regarding adenomas, there were no significant differences in their distribution in relation to CEPS type (type 1, $n = 7$; type 2, $n = 3$; $P = 0.5$). All 10 patients with adenoma were female (male, $n = 0$; female, $n = 10$; $P = 0.001$).

Thus, in this cohort, 33% of female patients developed adenomas.

Twenty of the 25 patients with benign nodules had at least one imaging study during follow-up (median time from first to last imaging study, 9.8 years; range, 0.3-20.0). In most cases, size and number of nodules remained stable. However, a small increase in size was observed in 3 patients (median increase, 13 mm; range, 5-30), and additional nodules appeared during follow-up in 4 patients.

PaHT AND HPS

Ten patients had dyspnea at a median age of 18 years (range, 2-42). PaHT was diagnosed in 8 patients (in 6 it was the main symptom leading to CEPS diagnosis, with a mean pulmonary arterial pressure of 46.5 ± 5.3 mm Hg) and HPS in the other 2 (severe in both of them, with hypoxemia $\text{PaO}_2 < 50$ mm Hg requiring domiciliary oxygen). Pulmonary arterial circulation was evaluated with echocardiography ($n = 18$) and/or Swan-Ganz right heart catheterization ($n = 3$) in 19 of 37 (51%) asymptomatic patients, revealing PaHT in 2 patients (ages of 1 and 10 years, respectively). Sex, presence of other congenital malformations or cardiac defects, type of CEPS, development of HE, or nodules were not associated with presence of PaHT or HPS.

Cumulative incidence of at least one major CEPS complication (HE, PaHT, HPS, HCC, and adenoma) at 20, 30, and 40 years was 35%, 45%, and 58%, respectively (Fig. 2).

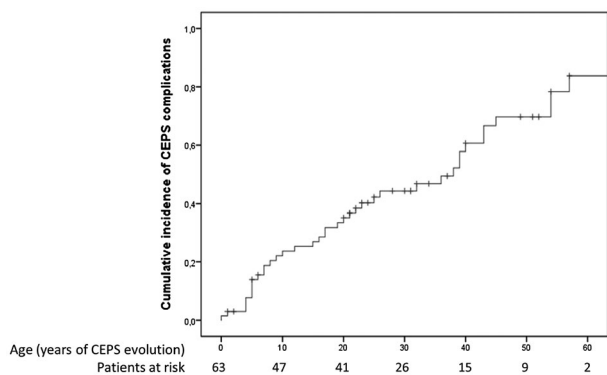


FIG. 2. Cumulative incidence of CEPS complications.

TREATMENT AND OUTCOME

Three of the 19 patients with HE presented subjective improvement with lactulose and rifaximin, whereas the other 16 presented persistent or recurrent HE despite receiving medical treatment. Four of the patients with persistent HE underwent shunt closure resulting in cognitive improvement and a decrease in ammonia blood level in all of them. One of them had a brain MRI 2 years after shunt closure showing a reduction in GP hyperintensity. Two of the patients with HE underwent LT (1 because he presented HCC and the other adenoma), and they evolved with resolution of HE.

Seven of the 10 patients with PaHT remained stable with specific medical treatment (median follow-up, 7.5 years; range, 0–37). The other 3 patients underwent shunt closure, observing a clear clinical improvement in 2 patients (in 1 confirmed also by cardiopulmonary catheterization) and making it possible to stop medical treatment. The main differences between the 2 patients improving after shunt closure and the 1 patient in whom there was no discernible improvement were as follows: younger age (23 and 24 vs. 34 years), lower mean pulmonary pressure (44 and 49 vs. 51 mm Hg), and shorter duration since diagnosis of PaHT (2 and 16 vs. 29 years) in those that improved.

Two patients with HPS underwent shunt closure, both at the age of 41, which was followed by resolution of hypoxemia and dyspnea 1 month and 1 year after the procedure, respectively.

Among the 8 patients with HCC, 1 patient presented an acute hemoperitoneum and died shortly

afterward. Six patients were submitted to surgical hepatectomy: 3 showed no HCC recurrence after a median follow-up of 36 months (range, 4–48) after surgery, whereas the other 3 developed HCC recurrence after a median of 44 months (range, 38–48), 1 of them eventually dying. One patient with concomitant HE underwent LT without further complications and was free of disease after 6 months of follow-up.

Of 10 patients with adenomas, 3 were treated with surgical hepatectomy and had no complications after a median follow-up of 12 months (range, 3–84). Five were transplanted (1 of them with concomitant HE) and, among them, 1 died 5 months later because of septic complications. One patient underwent shunt closure, but no changes in adenoma size (120 mm) were observed after 2 years of follow-up. An additional patient with a small adenoma (11 mm) was managed conservatively and remained stable after 4 years of follow-up.

In 5 asymptomatic patients, shunt closure was performed as a preemptive measure at a median age of 20 years (range, 5–31). No complications were registered until the end of their follow-up (median of 5.5 years after shunt closure; range, 1–12). Interestingly, 4 of these 5 patients presented benign nodules and all of them experienced a decrease in their size and/or number.

Overall, 15 patients (23%) underwent shunt closure; their main features according to the type of CEPS are summarized in Table 3. The main indication was chronic HE in 4 patients, PaHT in 3 patients, HPS in 2 patients, presence of a large adenoma in 1 patient, and preemptive in 5 patients. Shunt closure was performed at a median age of 17.5 years (range, 3–41) using a surgical ligation in 11 patients and a percutaneous endovascular technique in the remaining 4 patients. The election of surgical versus endovascular approach was guided mainly by the size of the shunt. Eight patients had type 1 and the other 7 had type 2 CEPS. It is important to underline that in the 8 type 1 CEPS patients, the intrahepatic portal vein branches were identified when a shunt occlusion was performed, in contrast with the lack of connection between the portal venous axis and the intrahepatic circulation described by the conventional imaging studies.

In 6 patients, the procedure was done in two steps to facilitate progressive redirection of portal blood flow to the liver. Remarkably, in 1 patient with type

TABLE 3. Shunt Closure Main Features According to CEPS Type

	Type 1 CEPS		Type 2 CEPS	
Shunt closure	8		7	
Technique				
Surgical	5		6	
Endovascular	3		1	
Steps				
One step	5		4	
Two steps	3		3	
Indication				
PaHT	2	Resolution in 1	1	Resolution
HPS	0		2	Resolution
HE	4	Improvement in all	0	
Adenoma	1	No changes	0	
Prophylactic	1	No complications	4	No complications
Complications	1		0	

1 CEPS, the occlusion test showed a marked increase in portal pressure without adequate drainage, making a transjugular intrahepatic portosystemic shunt placement deemed to decompress the portal venous system before completing shunt closure (Supporting Fig. S2). Probably because of these safety precautions, only 1 of the 15 patients with shunt closure presented a thrombosis of the mesenteric and splenic vein, a complication directly attributable to the shunt closure procedure. This patient was on anticoagulation during 1 year, but no regression of the thrombus was achieved. In the other 14 patients, there were neither portal-hypertension-related complications nor signs of bowel ischemia. None of the 15 patients developed new CEPS complications after a median of 2.5 years of follow-up after shunt closure (range, 0–12). In 4 of the 15 patients, a median increase of 428 cm³ (range, 179–598) in liver volume was reported.

There were 21 patients (32%) without major complications of CEPS that remained asymptomatic without being submitted to any intervention until the end of their follow-up at a median age of 33 years (range, 5–67).

Discussion

CEPS is an infrequent malformation characterized by the presence of a communication between the portal vein (or one of its afferent veins) and the IVC diverting the blood flow to the systemic circulation. These alterations in the splanchnic circulation produce

hemodynamic and physiological changes that lead to severe complications. Nevertheless, knowledge about CEPS is scarce given that the low incidence of this malformation has prevented the realization of large studies. In the current study, we have retrospectively enrolled 66 patients with congenital extrahepatic portosystemic shunts, thus presenting the largest series of patients with CEPS up to now with a long follow-up with >80% of patients achieving adulthood. This has allowed us to further characterize the manifestations and course of CEPS and analyze current management strategies. The study points out the highly variable approaches among the different centers. Based both on our results and on previous reports, we suggest a workup for CEPS in an attempt to homogenize its management.

The results of the current study show that patients with CEPS can remain asymptomatic until late in the disease and be undiagnosed until an advanced age. This is in contrast with previous case reports and series, where approximately 75% of CEPS were diagnosed during childhood.^(3,16,19,25,26) However, because most of the participating centers take care of adult patients, a bias evaluating the age of our patients at diagnosis cannot be discarded.

In the current cohort, CEPS proved to be a severe and life-threatening condition in many patients (68% of patients included in the study developed severe complications related to CEPS). It is important to underline that we may be underestimating the real incidence of CEPS complications given that some of them can be present but asymptomatic and remain

undiagnosed if not specifically screened for. Similarly, however, given that data from a systematic population screening are not available, we also cannot estimate the burden of uncomplicated patients with CEPS that remain undiagnosed and that may never develop symptoms.

In agreement with previous small series,⁽²⁷⁾ HE was the main complication in our cohort affecting more than 1 in every 4 patients. This is highly relevant given that even mild and minimal HE have proven to diminish quality of life. The present study was unable to identify any clinical or biochemical parameter (including ammonia levels) able to predict HE development. Of the 47 patients without overt HE, minimal HE was only evaluated in 2 patients. Minimal HE could present in atypical forms and be difficult to detect if not suspected, especially in patients with CEPS that frequently present associated congenital malformations and intellectual disabilities. Thus, future studies systematically evaluating the presence of minimal HE are warranted.

It is possible, however, that the finding of high GP intensity in brain MRI in patients without HE could identify patients at a higher risk of developing HE or having minimal HE. Nevertheless, our data also show that the lack of high GP intensity in brain MRI cannot confidently exclude the presence of HE in equivocal cases because this alteration was absent in 20% of cases with clear overt HE. Unfortunately, the number of patients without HE studied with brain MRI was very small, precluding any definitive conclusion. It will be of great interest to include brain MRI in the workup of newly diagnosed patients with CEPS.

Our study also suggests that HE may be bimodal, with most patients developing HE before the age of 25, but with a second rise in new-onset HE after the age of 50. Although we do not have an explanation for this finding, we can speculate that loss of brain reserve associated with aging may facilitate the revelation of HE.⁽²⁸⁾

Liver nodules have been previously described in as much as 40% of the reported patients with CEPS, being mainly focal nodular hyperplasia and regenerative nodular hyperplasia (70%). HCC (20%) and adenomas (10%) have been described in a lower proportion.⁽¹⁶⁻¹⁹⁾ In our study, the overall cumulative incidence of liver nodules was higher than previously reported,^(4,20,27) reaching 65% of patients. More important, a relevant and higher proportion of

patients than previously described in the literature had adenomas and HCC, probably in the context of better imaging accuracy in recent years and also in relation to the older age of our patients. In this regard, even though pediatric patients with CEPS have been described to develop HCC,⁽²⁹⁾ in our cohort HCC was a late complication appearing after the age of 30.

Previous observations suggested that the development of liver nodules (regardless of their nature) is more frequent in type 1 CEPS than in type 2 CEPS.^(17,18) In our cohort, this was the case only for HCC, which appeared almost exclusively in type 1 CEPS, probably in the setting of more severe alterations in liver perfusion and excessive arterialization attributed to the lack of portal blood flow.⁽³⁰⁾ In our series, HCCs were observed almost exclusively in men, whereas adenomas were observed only in women. This sex predilection is similar to that observed in the general population and does not have a clear explanation. However, evidence suggests that HCC is an androgen-sensitive tumor,⁽³¹⁾ and that the increased estrogen levels of females may enhance the risk of developing benign liver tumors.⁽³²⁾ Nevertheless, it should be noted that adenomas have been also reported in males with CEPS in the literature.⁽¹⁹⁾ These data suggest the need of performing a careful and periodic screening for liver nodules in patients with CEPS, and therefore it would seem sensible to adopt the cirrhosis strategy of HCC surveillance every 6 months.

Patients with CEPS have been reported to develop severe pulmonary complications, such as PaHT.^(19,33) and, less frequently, HPS.^(14,27) The development of HPS and PaHT could be in relation to intestinal vasoactive mediators^(14,15,34) that, having bypassed the liver and not being properly metabolized, reached the pulmonary vascular bed, inducing a long-standing pulmonary vasoconstriction in the case of PaHT^(15,16) or, on the contrary, pulmonary vasodilation in the case of HPS. Our study confirms that PaHT is a significant problem in patients with CEPS, causing symptomatic dyspnea in 80% of cases. Moreover, in this cohort, 11% of asymptomatic patients also presented PaHT when specifically screened for it. Because PaHT was identified at a wide range of age, screening for PaHT may be worthy to be repeated during follow-up. Because performing periodic cardiac catheterization can be inconvenient, it seems reasonable to recommend using an echocardiogram for follow-up PaHT screening.

The study should be subsequently completed with cardiopulmonary catheterization if indirect signs of PaHT were found. HPS appears to be less frequent than PaHT, with prevalence in our study of 3%. However, given that mild forms of HPS might be asymptomatic and an exhaustive pulmonary study was not performed in all the patients of our cohort, its real prevalence cannot be estimated. It would be advisable to perform a baseline exhaustive screening of pulmonary complications, and afterward periodic screening with transcutaneous oxygen saturation measurements could be helpful for early detection of its appearance during follow-up.

Fifteen patients (23%) were submitted to shunt closure, at a median age of 17 years, but as young as at 3 years and as late as at 41 years. It is important to remark that shunt closure restoring portal blood flow to the liver was possible even in patients with type 1 CEPS. This reinforces the theory that the assessment of intrahepatic portal vein patency based only in CT scan or MRI without performing an occlusion test might be misleading because residual hypoplastic veins might be only recognized through balloon occlusion venography, as shown by several previous reports.^(3,4,19,27,35,36) The current study

confirms this relevant finding given that in all type 1 CEPS patients that underwent an occlusion test, remnants of the intrahepatic portal vein branches were identified. Establishing confidently the presence or absence of intrahepatic veins is highly relevant when evaluating possible therapeutic options, given that classically type 1 patients could only be treated with LT. Nevertheless, the type 1 and 2 CEPS classification is still useful because, even if the intrahepatic portal vein branches may be also present in type 1 CEPS, they are hypoplastic and leading less, if any, flow to the liver,⁽³⁾ which could have pathophysiological consequences like more frequent HCC development as we have observed in our cohort.

Shunt closure was always performed after checking that the procedure was associated with an adequate redirection of portal blood flow to the liver, usually requiring a two-step intervention promoting the stenosis of the portal-collateral circulation with the ensuing increase in the portal system pressure leading to the reopening of the hypoplastic portal branches. Some researchers have suggested that prophylactic anticoagulation could also be useful to prevent thrombosis after shunt closure.^(19,20) Our results coincide with previous

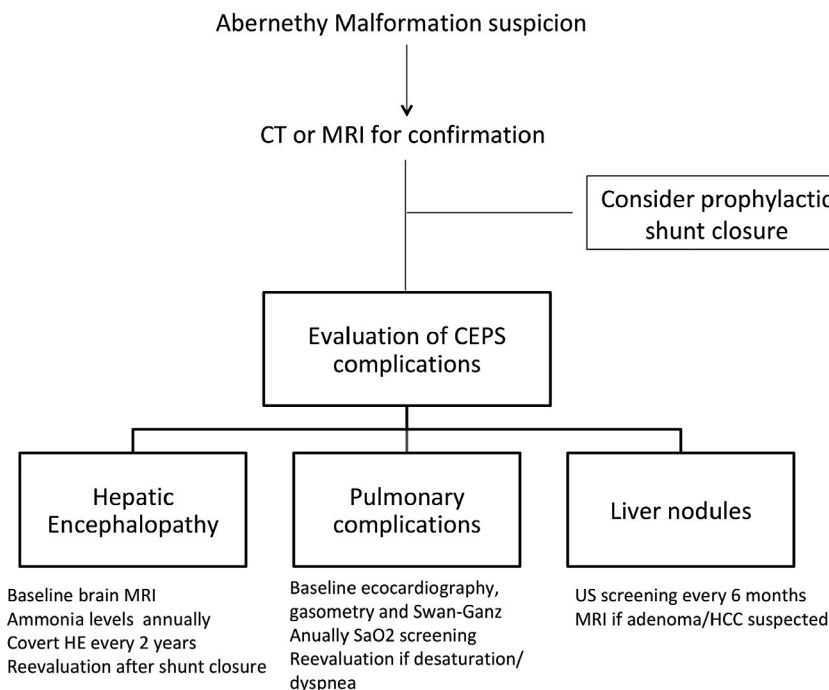


FIG. 3. CEPS management algorithm.

reports,^(5,16) suggesting that shunt closure has a huge efficacy managing most CEPS complications and, most interestingly, preventing its appearance. Therefore, shunt closure must be always considered in symptomatic patients and should also be considered as a prophylactic treatment early in the evolution of the disease to prevent the development of severe complications. Nevertheless, it cannot be assured that the risk of complications completely disappears with the occlusion of the shunt, and thus HCC surveillance should still be performed until more data are available.

In the current cohort, shunt closure was especially useful in improving HE, but was less effective in patients with long-standing and severe PaHT, probably because the highest the pressure, the less improvement after closure can be expected. Although the only patient with adenoma in our cohort did not improve after shunt closure, partial adenoma regression after shunt closure has been reported.⁽¹⁹⁾

The present study shows that the current diagnostic and therapeutic approach of CEPS is highly variable depending on each center policy. We consider that consensus guidelines would improve the knowledge of the disease and the management of these patients. Thus, based on the results of our cooperative study, in Fig. 3 we propose a management algorithm for all patients with CEPS.

This is the largest CEPS cohort until now and the only one in which most patients have reached adulthood at the end of follow-up, which could explain some of the clinical differences found in comparison with previous reports. CEPS patients may develop significant morbidity and life-threatening complications. Therefore, screening for asymptomatic complications and close surveillance is needed. Shunt closure should be considered both in a therapeutic and prophylactic approach.

Appendix

Abernethy Group: Ángeles García-Criado, Anna Darnell, Ernest Belmonte, José Ferrusquía-Acosta, Marta Magaz, Judit Vidal-González, Stefanescu Horia, Oana Nicoara-Farcau, Philip Joseph, Uday Zachariah, Vinu Moses, Suraj Mammen, Munawwar Ahmed, George Koshy, Anu Eapen, K.G. Sajith, F.L. Vyas, R.S. Raju, Manbha L. Rymbai, S. Arulkumar, Jayamani Ramachandran, and Elwyn Elias.

REFERENCES

- 1) Glyn Morgan RS. Congenital absence of the portal vein: two cases and a proposed classification system for portosystemic vascular anomalies. *J Pediatr Surg* 1994;29:1239-1241.
- 2) Howard ER, Davenport M. Congenital extrahepatic portocaval shunts—the Abernethy malformation. *J Pediatr Surg* 1997;32:494-497.
- 3) Lautz TB, Tantemsapya N, Rowell E, Superina RA. Management and classification of type II congenital portosystemic shunts. *J Pediatr Surg* 2011;46:308-314.
- 4) Blanc T, Guerin F, Franchi-Abella S, Jacquemin E, Pariente D, Soubrane O, et al. Congenital portosystemic shunts in children: a new anatomical classification correlated with surgical strategy. *Ann Surg* 2014;260:188-198.
- 5) Franchi-Abella S, Gonzales E, Ackermann O, Branchereau S, Pariente D, Guérin F, et al. Congenital portosystemic shunts: diagnosis and treatment. *Abdom Radiol (NY)* 2018;43:2023-2036.
- 6) Kanazawa H, Nosaka S, Miyazaki O, Sakamoto S, Fukuda A, Shigeta T, et al. The classification based on intrahepatic portal system for congenital portosystemic shunts. *J Pediatr Surg* 2015;50:688-695.
- 7) Witters P, Maleux G, George C, Delcroix M, Hoffman I, Gewillig M, et al. Congenital veno-venous malformations of the liver: widely variable clinical presentations. *J Gastroenterol Hepatol* 2008;23(8 Pt 2):e390-e394.
- 8) Konstas AA, Digumarthy SR, Avery LL, Wallace KL, Lisovsky M, Misdraji J, et al. Congenital portosystemic shunts: Imaging findings and clinical presentations in 11 patients. *Eur J Radiol* 2011;80:175-181.
- 9) Stringer MD. The clinical anatomy of congenital portosystemic venous shunts. *Clin Anat* 2008;21:147-157.
- 10) Gitzelmann R, Forster I, Willi UV. Hypergalactosaemia in a newborn: self-limiting intrahepatic portosystemic venous shunt. *Eur J Pediatr* 1997;156:719-722.
- 11) Ono H, Mawatari H, Mizoguchi N, Eguchi T, Sakura N. Clinical features and outcome of eight infants with intrahepatic porto-venous shunts detected in neonatal screening for galactosaemia. *Acta Paediatr* 1998;87:631-634.
- 12) Akaoshi T, Nishizaki T, Wakasugi K, Mastuzaka T, Kume K, Yamamoto I, et al. Portal-systemic encephalopathy due to a congenital extrahepatic portosystemic shunt: three cases and literature review. *Hepatogastroenterology*. 2000;47:1113-1116.
- 13) Uchino T, Matsuda I, Endo F. The long-term prognosis of congenital portosystemic venous shunt. *J Pediatr* 1999;135:254-256.
- 14) Fu L, Wang Q, Wu J, Guo Y, Huang M, Liu T, et al. Congenital extrahepatic portosystemic shunt: an underdiagnosed but treatable cause of hepatopulmonary syndrome. *Eur J Pediatr* 2016;175:195-201.
- 15) Yi JE, Jung HO, Youn HJ, Choi JY, Chun HJ, Lee JY. A case of pulmonary arterial hypertension associated with congenital extrahepatic portocaval shunt. *J Korean Med Sci* 2014;29:604-608.
- 16) Sokollik C, Bandsma RHJ, Gana JC, van den Heuvel M, Ling SC. Congenital portosystemic shunt: characterization of a multisystem disease. *J Pediatr Gastroenterol Nutr* 2013;56:675-681.
- 17) Sharma R, Suddle A, Quaglia A, Peddu P, Karani J, Satyadas T, et al. Congenital extrahepatic portosystemic shunt complicated by the development of hepatocellular carcinoma. *Hepatobiliary Pancreat Dis Int* 2015;14:552-557.
- 18) Sorokin T, Strautnieks S, Foskett P, Peddu P, Thompson RJ, Heaton N, et al. Case report: multiple beta-catenin mutations in hepatocellular lesions arising in Abernethy malformation. *Hum Pathol* 2016;53:153-158.

- 19) Franchi-Abella S, Branchereau S, Lambert V, Fabre M, Steimberg C, et al. Complications of congenital portosystemic shunts in children: therapeutic options and outcomes. *J Pediatr Gastroenterol Nutr* 2010;51:322-330.
- 20) Chocarro G, Virginia M, Jose A, Encinas L, Vilanova A, Hernandez F, et al. Congenital portosystemic shunts : clinic heterogeneity requires an individual management of the patient. *Eur J Pediatr Surg* 2016;26:74-80.
- 21) Francois B, Gottrand F, Lachaux A, Boyer C, Benoit B, De Smet S. Outcome of intrahepatic portosystemic shunt diagnosed prenatally. *Eur J Pediatr* 2017;176:1613-1618.
- 22) Vicente N, Pérez M, Gander R, Segarra A, Leganés C, Bueno J. [Congenital portosystemic shunt. Importance of early treatment]. [Article in Spanish; Abstract available in Spanish from the publisher] *Cir Pediatr* 2015;28:67-73.
- 23) Nacif LS, Paranaçu-Vezozzo DC, Galvão FHF, Rocha MS, Andraus W, Carrilho FJ, et al. Significance of CT scan and color Doppler duplex ultrasound in the assessment of Abernethy malformation. *BMC Med Imaging* 2015;15:37.
- 24) Witjes CDM, Ijzermans JNM, Noordegraaf AV, Tran TCK. Management strategy after diagnosis of Abernethy malformation: a case report. *J Med Case Rep* 2012;6:167.
- 25) Gong Y, Zhu H, Chen J, Chen Q, Ji M, Pa M, et al. Congenital portosystemic shunts with and without gastrointestinal bleeding—case series. *Pediatr Radiol* 2015;45:1964-1971.
- 26) Ikeda S, Sera Y, Ohshiro H, Uchino S, Uchino T, Endo F. Surgical indications for patients with hyperammonemia. *J Pediatr Surg* 1999;34:1012-1015.
- 27) Guérin F, Blanc T, Gauthier F, Abella SF, Branchereau S. Congenital portosystemic vascular malformations. *Semin Pediatr Surg* 2012;21:233-244.
- 28) Amodio P, Montagnese S, Spinelli G, Schiff S, Mapelli D. Cognitive reserve is a resilience factor for cognitive dysfunction in hepatic encephalopathy. *Metab Brain Dis* 2017;32:1287-1293.
- 29) Benedict M, Rodriguez-Davalos M, Emre S, Walther Z, Morotti R. Congenital extrahepatic portosystemic shunt (Abernethy malformation type Ib) with associated hepatocellular carcinoma: case report and literature review. *Pediatr Dev Pathol* 2017;20:354-362.
- 30) Gülşen Z, Yiğit H, Demir P. Multiple regenerative nodular hyperplasia in the left infrarenal vena cava accompanied by Abernethy malformation. *Surg Radiol Anat* 2016;38:373-378.
- 31) Naugler WE, Sakurai T, Kim S, Maeda S, Kim K, Elsharkawy AM, et al. Gender disparity in liver cancer due to sex differences in MyD88-dependent IL-6 production. *Science* 2007;317:121-124.
- 32) Baek S, Sloane CE, Futterman SC. Benign liver cell adenoma associated with use of oral contraceptive agents. *Ann Surg* 1976;183:239-242.
- 33) Ohno T, Muneuchi J, Ihara K, Yuge T, Kanaya Y, Yamaki S, et al. Pulmonary hypertension in patients with congenital portosystemic venous shunt: a previously unrecognized association. *Pediatrics* 2008;121:e892-e899.
- 34) Morikawa N, Honna T, Kuroda T, Kitano Y, Fuchimoto Y, Kawashima N, et al. Resolution of hepatopulmonary syndrome after ligation of a portosystemic shunt in a pediatric patient with an Abernethy malformation. *J Pediatr Surg* 2008;43:e35-e38.
- 35) Murray CP, Yoo SJ, Babyn PS. Congenital extrahepatic portosystemic shunts. *Pediatr Radiol* 2003;33:614-620.
- 36) Yonemitsu H, Mori H, Kimura T, Kagawa K, Tsuda T, Yamada Y, et al. Congenital extrahepatic portocaval shunt associated with hepatic hyperplastic nodules in a patient with Dubin-Johnson syndrome. *Abdom Imaging* 2000;25:572-575.

Supporting Information

Additional Supporting Information may be found at onlinelibrary.wiley.com/doi/10.1002/hep.30817/supinfo.