

## Avian Pox in White-tailed Laurel-pigeons from the Canary Islands

Félix Manuel Medina,<sup>1,4</sup> Gustavo Adolfo Ramírez,<sup>2</sup> and Antonio Hernández<sup>3,1</sup> Unidad de Medio Ambiente, Cabildo Insular de La Palma, Av. Bajamar 20, 2°, 38700 Santa Cruz de La Palma, La Palma, Canary Islands, Spain; <sup>2</sup> Department of Comparative Pathology, Veterinary Faculty, Universidad de Las Palmas de Gran Canaria, Gran Canaria, Canary Islands, Spain; <sup>3</sup> C/Esteban Pérez González, 18, 38710 Breña Alta, La Palma, Canary Islands, Spain; <sup>4</sup> Corresponding author (email: felix.medina@cablalpalma.es)

**ABSTRACT:** Two diseased young white-tailed laurel-pigeons (*Columba junoniae*), an endemic and endangered species of the Canary Islands (Spain), were found in La Palma. They were very depressed and had severe cutaneous yellowish nodular lesions in feathered and unfeathered areas on the bodies of both birds. Necropsy and histopathologic analyses were conducted. The presence of epidermal hypertrophy and hyperplasia in cutaneous lesions, as well as several acidophilic intracytoplasmic inclusions in affected epithelial cells (Bollinger bodies), confirmed avian poxvirus infection. This is the first report of avian pox in white-tailed laurel-pigeons or in any other free-ranging bird in the Canaries, and it might indicate that other threatened birds of the Canarian Archipelago may be affected by this viral disease.

**Key words:** Avian pox, Canary Islands, *Columba junoniae*, endemic bird, La Palma, poxvirus, white-tailed laurel-pigeon.

Poxviruses are among the largest and most complex viruses known and are members of the genus *Avipoxvirus* of the family *Poxviridae* (Tripathy, 1991; Boulanger et al., 2000). Avian pox is a well-known disease in chickens, turkeys, pigeons, and canaries, and it has been identified in >60 wild bird species (Tripathy, 1991). Avian pox is a transmissible disease that is spread by several kinds of vectors: biting arthropods such as mosquitoes and mites (Proctor and Owens, 2000), aerosols generated from infected birds, or the ingestion of contaminated food or water (Clubb, 1986). The disease has two forms: cutaneous and diphtheritic. The cutaneous form is characterized by epidermal lesions on featherless areas of the body, whereas fibrinonecrotic and proliferative lesions in the mouth, esophagus, and mucous membranes of the upper respiratory tract are characteristics of the diphtheritic form (Tripathy, 1991).

The white-tailed laurel-pigeon (*Columba junoniae* Hartert, 1916) is an endemic

species of the Canary Islands that is present on the western islands of the archipelago: Tenerife, La Palma, La Gomera, and El Hierro (Fig. 1). The main populations of this species live in La Palma, because this island has the highest area of relict laurel forest of the Canary Islands (Martín et al., 2000). The white-tailed laurel-pigeon is primarily distributed in the laurel forest, although it may occupy other forest types (pine and temperate), as well as cultivated areas.

Management and conservation programs for wild, threatened, and endemic bird species need information about diseases in these populations. For this reason, we document the first cases of avian pox disease detected in white-tailed laurel-pigeons.

Between October 2000 and August 2001, two diseased young white-tailed laurel-pigeons were found close together on La Palma, Canary Islands (Spain, 28°47'51.8"N, 17°47'18.9"W). Both birds were captured by local people in disturbed zones (road and banana crops), appeared to be depressed, had wet droppings, and had several yellow cutaneous tumor-like lesions, predominantly on the unfeathered areas of their bodies (Fig. 2).

Bird 1 (Fig. 2A) was found on 5 October 2000. The bird was lethargic, dehydrated, and emaciated. Multiple 1-cm-diameter masses were noted on unfeathered areas of the head at the base of the beak, rim of the mouth, the periocular area and legs. The masses were coalescing, round, yellowish, and fibrotic, and some were superficially ulcerated. Physiologic saline was administered subcutaneously to correct dehydration, in conjunction with vitamin A (10,000–25,000 UI/300 g, once), but the bird died after about 2 hr.

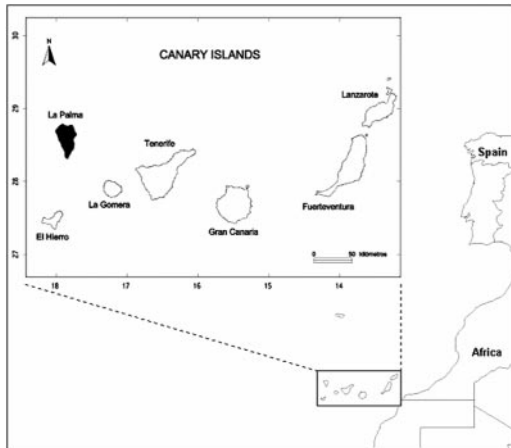


FIGURE 1. Map of the Canary Islands (Spain) showing the location of La Palma.

Bird 2 (Fig. 2B) was found on 27 August 2001. It was also depressed, dehydrated, and emaciated. Serous bilateral conjunctivitis was noted. Several 0.5–1 cm-diameter coalescing, round, yellowish, rough, and firm masses were found at the base of the beak, mouth, eyelids, legs, wings, and the anal and uropygial regions. Symptomatic treatment as described for bird 1 was attempted, but the bird died within 2 hr of being found. At necropsy, no gross abnormalities other than skin lesions were observed. Diphtheritic lesions were not found in either bird.

Tissues collected from bird 2 were sent to a diagnostic pathology laboratory (Veterinary Pathology Laboratory, Las Palmas de Gran Canaria University, Gran Canaria, Canary Islands, Spain). Tissue samples were fixed in 10% buffered formalin, embedded in paraffin, cut at 5  $\mu\text{m}$ , and stained with hematoxylin and eosin. Histologic sections of skin containing the nodular lesions had cords and large clusters of markedly hypertrophic and hyperplastic epidermal stratified squamous epithelium, surrounded by dense fibroblastic stroma (Fig. 3). Cords of epithelium invaded the underlying dermis. Lesions consisted of swollen and pale keratinocytes with a foamy, vacuolated cytoplasm and single, round, dense eosinophilic intracytoplasmic viral inclusions (identified as Bollinger bodies) (Fig. 3). Inclusions distended the cell cytoplasm, producing cell necrosis. Some of them had clear, unstained, central rounded spaces (Fig. 3). The superficial epidermis of the lesions was ulcerated with eosinophilic, amorphous keratinaceous crusts, necrosis, and abundant degenerated granulocytes (Fig. 3). Bacteria were observed within necrotic tissue.

Multiple small, necrotic foci composed of necrotic hepatocytes with indistinct cell boundaries and scarce granulocytes were




FIGURE 2. Nodular yellowish cutaneous lesions in two white-tailed laurel-pigeons (*Columba junoniae*) infected with avian poxvirus. A: bird 1; B: bird 2.

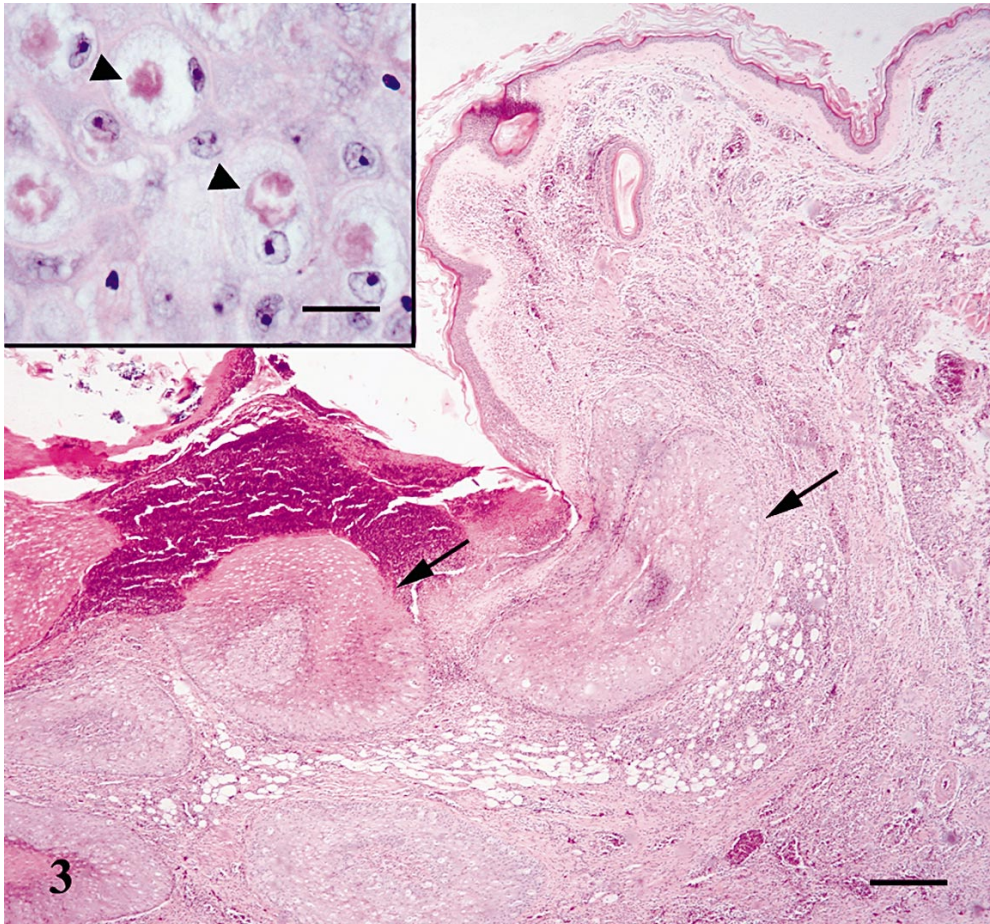


FIGURE 3. Histologic section showing ulceration and necrosis of the epidermis with superficial crusting formation and dermal inflammatory infiltrate. Note nodular lesions (arrows) representing severe marked hyperplasia of the squamous epithelium. 40 $\times$ . Hematoxylin and eosin stain. Bar = 2 mm. Inset. Numerous typical acidophilic inclusions (Bollinger bodies; arrowheads) distending the cytoplasm of affected epithelial cells. Central unstained spaces are caused by fat dissolving from the inclusions during tissue processing. 1,000 $\times$ . Hematoxylin and eosin stain. Bar = 80  $\mu$ m.

evident in the liver. Acute necrosis of the epithelium of proximal convoluted tubules was seen in the kidney. Gram-negative bacterial colonies were present in liver, lung, proventriculus, and kidney. No changes were observed in other organs.

On the basis of necropsy results, histopathologic features, and the presence of viral intracytoplasmic inclusions in epidermal cells, a diagnosis of poxvirus infection was made. In some cases, the diagnosis of a pox virus infection can be suspected by external clinical examination and gross le-

sions (Cooper, 1985; Heuschele, 1986), but it is necessary to confirm the disease in the cutaneous form by the presence of characteristic Bollinger bodies in epithelial cells of epidermis observed in histopathologic analysis, by electron microscopy for viral particles in epidermal cells, or by virus isolation (Heuschele, 1986; Tripathy, 1991; Randall and Reece, 1996). In our birds, gross lesions were compatible with an avian pox diagnosis, and this fact was confirmed by the histopathologic analysis performed on bird 2.

Mortality and morbidity due to poxvirus infection may be very high in pigeons (Tripathy, 1991). Nevertheless, poxvirus is not fatal in all infected individuals, but it can reduce viability and predispose affected birds to predation, secondary infection, and accident (Reece, 1989). The development of cutaneous lesions occurs in 2 wk, with the formation of yellow scabs and desquamation of necrotic epithelium (Tripathy, 1991). In our cases, the birds had prominent yellow nodular cutaneous lesions. Secondary bacterial infection was present in bird 2. Histopathologic features and negative Gram staining were suggestive of *Salmonella* sp. infection; unfortunately, cultures for bacteria were not done. We believe that poxvirus infection was an important, if not the direct, cause of death in bird 1. In bird 2, disseminated bacterial infection, possibly secondary to the poxvirus infection, was probably the cause of death.

There is no specific treatment for avian poxvirus infection (Redig, 1979; Boulanger et al., 2000). Treatments include the use of antibiotics to control bacterial infections, vitamin A to aid healing (Cooper, 1985), and immunization (Boulanger et al., 2000). Vaccination is very effective and has virtually eliminated the disease in the poultry industry. Taxon-specific vaccines are available for a few of the avian poxvirus types, even for pigeon pox (Woodward and Tudor, 1973; Clubb, 1986), but administration routes of the vaccine (chickens and pigeons are usually vaccinated by the wing web stick method) are difficult to use in free-ranging species. As other authors have stated, we do not think it is feasible to use vaccination to control pigeon pox in free-flying birds (Tripathy, 1991; Boulanger et al., 2000).

Habitat loss and fragmentation, illegal hunting, and predation by introduced mammals such as rats (*Rattus* sp.) and cats have been reported to be the principal threats of the endemic pigeons of the Canary Islands (Hernández et al., 1999; Martín et al., 2000). The role of humans in the

spread of poxvirus may be important, because domestic and wild birds are being brought together in the same habitats (Metz et al., 1985). White-tailed laurel-pigeons have a wide distribution on this island that could imply an increased likelihood of contact with domestic and wild pigeons and a consequent increased infection rate in this threatened species.

The effect of the avian poxvirus in the white-tailed laurel-pigeon and other endemic birds in the Canary Islands is unknown because of the difficulty in detecting diseased and/or dead birds in nature. This disease could be an important factor in the decrease in populations of these birds in the Canary Islands, as has been reported on island ecosystems such as Hawaii (USA) for other forest birds species (Cooper, 1989; Clark, 1998).

This is the first report of avian poxvirus infection in white-tailed laurel-pigeons. This could indicate that other threatened birds of the Canary Archipelago may also be affected by this viral disease. The presence of avian pox in white-tailed laurel-pigeon should be considered as a new conservation problem in this endangered species and possibly a problem for management and conservation of other endemic and threatened bird species in island ecosystems.

We acknowledge A. Espinosa de los Monteros, A. Martín, and M. Nogales, who made helpful comments to an early draft of this manuscript. P. Pérez and F. Sánchez showed us the location of the infected pigeons.

#### LITERATURE CITED

- BOULANGER, D., T. SMITH, AND M. A. SKINNER. 2000. Morphogenesis and release of fowlpox virus. *Journal of General Virology* 81: 675–687.
- CLARK, J. R. 1998. Endangered and threatened wildlife and plants: Proposed endangered status for the Oahu elepaio from the Hawaiian Islands. Federal Register Document 63: 53623–53631.
- CLUBB, S. L. 1986. Avian pox in cage and aviary birds. *In Zoo and wild animal medicine*, 2nd Edition, M. E. Fowler (ed.). W. B. Saunders Company, Philadelphia, Pennsylvania, pp. 213–219.
- COOPER, J. E. 1985. Veterinary aspects of captive

- birds of prey: With 1985 supplement. The Standard Press, Cherington, UK, 256 + 31 pp.
- . 1989. The role of pathogens in threatened populations: An historical review. *In* Disease and threatened birds, J. E. Cooper (ed.). ICBP technical publication 10. International Council for Bird Preservation, Cambridge, UK, pp. 51–61.
- HERNÁNDEZ, M. A., A. MARTÍN, AND M. NOGALES. 1999. Breeding success and predation on artificial nests of the endemic pigeons Bolle's laurel pigeon *Columba bollii* and white-tailed laurel pigeon *Columba junoniae* in the laurel forest of Tenerife (Canary Islands). *Ibis* 141: 52–59.
- HEUSCHELE, W. P. 1986. Infectious diseases. *In* Zoo and wild animal medicine, 2nd Edition, M. E. Fowler (ed.). W. B. Saunders Company, Philadelphia, Pennsylvania, pp. 57–62.
- MARTÍN, A., M. A. HERNÁNDEZ, J. A. LORENZO, M. NOGALES, AND C. GONZÁLEZ. 2000. Las palomas endémicas de Canarias. Viceconsejería de Medio Ambiente del Gobierno de Canarias and SEO/BirdLife, Santa Cruz de Tenerife, Spain, 191 pp.
- METZ, A. L., L. HATCHER, J. A. NEWMAN, AND D. A. HALVORSON. 1985. Venereal pox in breeder turkeys in Minnesota. *Avian Disease* 29: 850–853.
- PROCTOR, H., AND I. OWENS. 2000. Mites and birds: Diversity, parasitism and coevolution. *Trends in Ecology and Evolution* 15: 358–364.
- RANDALL, C. J., AND R. L. REECE. 1996. Integumentary system. *In* Color atlas of avian histopathology, C. J. Randall and R. L. Reece (eds.). Mosby-Wolfe, London, UK, pp. 43.
- REDIG, P. T. 1979. Infectious diseases. *In* First aid and care of wild birds, J. E. Cooper and J. T. Eley (eds.). Davis and Charles (Publishers) Limited, Newton Abbot, UK, pp. 118–139.
- REECE, R. L. 1989. Avian pathogens: Their biology and methods of spread. *In* Disease and threatened birds, J. E. Cooper (ed.). ICBP technical publication 10. International Council for Bird Preservation, Cambridge, UK, pp. 1–23.
- TRIPATHY, D. N. 1991. Pox. *In* Diseases of poultry, B. W. Calnek (ed.). Iowa State University Press, Ames, Iowa, pp. 583–596.
- WOODWARD, H., AND D. C. TUDOR. 1973. The immunizing effect of commercial pigeon pox vaccines on pigeons. *Poultry Sciences* 52: 1463–1468.

*Received for publication 31 January 2003.*