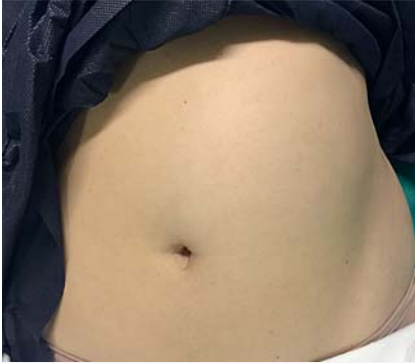

## Spontaneous hyperinflation of intragastric balloon: What caused it?



► **Fig. 1** The patient presented with abdominal pain and distension at 7 weeks after intragastric balloon placement. Examination revealed a visible bulge in the left upper quadrant. The distended balloon was easily palpable.

Intragastric balloons (IGBs) are an established, minimally invasive treatment option for obesity. Multiple studies have shown them to be safe and effective in achieving weight loss at 6 months and 1 year. IGBs with newer designs, various filling volumes, and longer indwelling

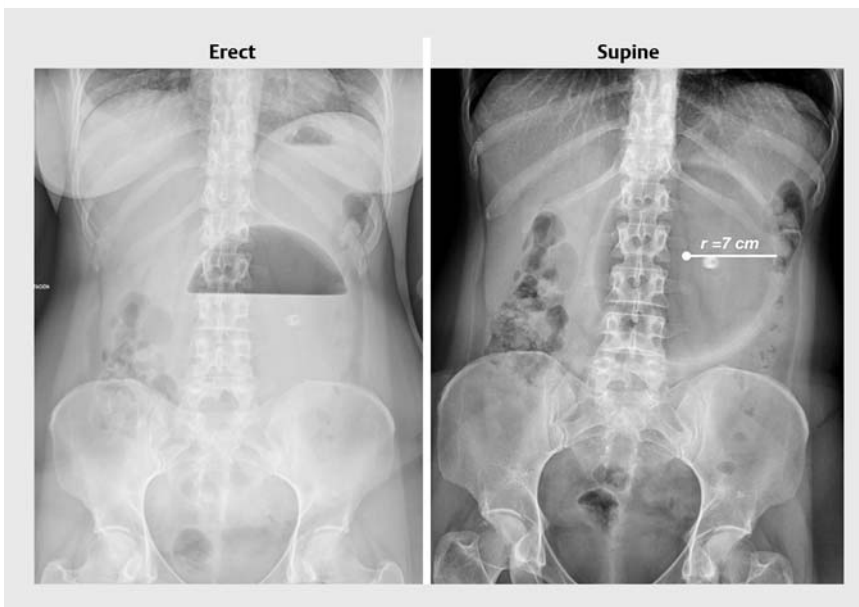
times are currently becoming available to minimize intolerance and improve patient adherence [1]. The overall reported rate of complications with IGBs is very low. However, when a complication does occur, it can be severe and debilitating [2]. In this video, we describe a relatively under-reported complication of IGBs.

A 42-year-old woman underwent endoscopic placement of an IGB for the treatment of obesity (weight 76 kg, body mass index 31 kg/m<sup>2</sup>). She did not have any co-morbidities. The stomach was normal, and we inflated the IGB (Orbera, Apollo Endosurgery, USA) with 650 mL of normal saline and 1% methylene blue. We discharged her with proton pump inhibitors and anti-emetic medications. She tolerated the IGB well. However, at 7 weeks, she presented with severe vomiting, abdominal pain, and distension. Examination revealed a distended left upper abdomen with a palpable IGB (► **Fig. 1**). Laboratory analysis showed metabolic alkalosis (pH 7.44, bicarbonate 21.7 mmol/L, potassium 3.7 mmol/L).

X-rays demonstrated a large air–fluid level, and massive enlargement of the IGB (~1437 mL) compared with its original volume (► **Fig. 2**). Repeat endoscopy showed a hyperinflated IGB causing pyloric obstruction, with no visible signs of microbial colonization (► **Fig. 3**, ► **Video 1**). We punctured the balloon and aspirated the mid-stream fluid for microbiological assessment; we then removed the balloon. The specimen culture showed *Candida parapsilosis*. The symptoms resolved entirely after IGB removal, and no antifungal treatment was administered.

*C. parapsilosis* can grow in the presence of high saline concentrations and can produce gas by fermentation, resulting in IGB hyperinflation [3, 4]. The nutritive environment and slow gastric emptying after IGB placement may have promoted the rapid colonization of *Candida* [5]. Early recognition and IGB removal may prevent serious complications.

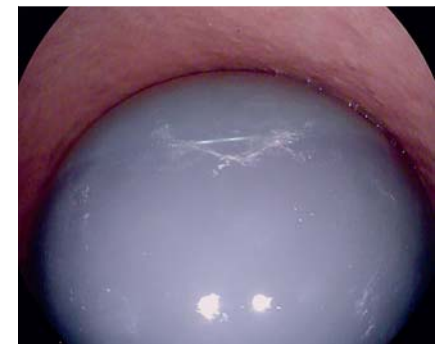Endoscopy\_UCTN\_Code\_CPL\_1AH\_2AJ



► **Fig. 2** Erect and supine X-ray images showed a grossly distended intragastric balloon. A large air–fluid level can be appreciated. Calculation of the volume ( $\frac{4}{3}\pi r^3$ ) showed the balloon was approximately twice its original volume.

### Competing interests

Dr. Gonrand Lopez-Nava is a consultant for Apollo Endosurgery, USA; USGI Medical, USA; and Nitinotes, Israel.



► **Fig. 3** Endoscopic view showed a distended balloon with an air–fluid level. The balloon was partially obstructing the pylorus and causing gastric outlet obstruction.

# Spontaneous Inflation of Intra-gastric Balloon- What Caused It?

Gontrand Lopez-Nava, MD, Ph.D., Ravishankar Asokkumar, MBBS, MRCP, Inmaculada Bautista, MD, Ph.D., Anuradha Negi, MBBS, MRCP

Bariatric Endoscopy Unit, HM Sanchinarro University Hospital, Madrid, Spain.

Department of Gastroenterology and Hepatology

Singapore General Hospital, Singapore.

Department of Endocrinology and Metabolism, Khoo Teck Puat Hospital,

Singapore



**Video 1** Hyperinflated intra-gastric balloon causing pyloric obstruction.

## Bibliography

DOI <https://doi.org/10.1055/a-1034-7671>

Published online: 2019

Endoscopy

© Georg Thieme Verlag KG

Stuttgart · New York

ISSN 0013-726X

## ENDOSCOPY E-VIDEOS

<https://eref.thieme.de/e-videos>



*Endoscopy E-Videos* is a free access online section, reporting on interesting cases and new

techniques in gastroenterological endoscopy. All papers include a high quality video and all contributions are freely accessible online.

This section has its own submission website at

<https://mc.manuscriptcentral.com/e-videos>

## The authors

**Gontrand Lopez-Nava**<sup>1,\*</sup>, **Ravishankar Asokkumar**<sup>1,2,\*</sup>, **Inmaculada Bautista**<sup>1</sup>, **Anuradha Negi**<sup>1,3</sup>

- 1 Bariatric Endoscopy Unit, HM Sanchinarro University Hospital, Madrid, Spain
- 2 Department of Gastroenterology and Hepatology, Singapore General Hospital, Singapore
- 3 Department of Endocrinology and Metabolism, Khoo Teck Puat Hospital, Singapore

## Corresponding author

**Gontrand Lopez-Nava, MD, PhD**

Bariatric Endoscopy Unit, HM Sanchinarro University Hospital, Calle de Oña, 10, 28050 Madrid, Spain  
 Fax: +34-91-7500203  
[glopeznava@digestivolopeznava.com](mailto:glopeznava@digestivolopeznava.com)

## References

- [1] Choi SJ, Choi HS. Various intra-gastric balloons under clinical investigation. *Clin Endosc* 2018; 51: 407–415
- [2] Stavrou G, Tsaousi G, Kotzampassi K. Life-threatening visceral complications after intra-gastric balloon insertion: Is the device, the patient or the doctor to blame? *Endosc Int Open* 2019; 7: E122–E129
- [3] Kotzampassi K, Vasilaki O, Stefanidou C et al. *Candida albicans* colonization on an intra-gastric balloon. *Asian J Endosc Surg* 2013; 6: 214–216
- [4] Krauke Y, Sychrova H. Four pathogenic *Candida* species differ in salt tolerance. *Curr Microbiol* 2010; 6: 335–339
- [5] de Quadros LG, Dos Passos Galvão Neto M, Grecco E et al. Intra-gastric balloon hyperinsufflation as a cause of acute obstructive abdomen. *ACG Case Rep J* 2018; 5: e69

\* These authors contributed equally to this work.