Research in Veterinary Science 1990, 49, 339–345

Immunohistochemical demonstration of *Mycoplasma gallinarum* and *Mycoplasma gallinaceum* in naturally infected hen oviducts

J. MARTIN DE LAS MULAS, A. FERNANDEZ, M. A. SIERRA, *Departamento de Anatomia y Patológica*, J. B. POVEDA, J. CARRANZA, *Departamento de Sanidad Animal, Facultad de Veterinaria, Avenida Medina Azahara, 14071 Córdoba, Spain*

Using indirect immunoperoxidase (IIP), peroxidase anti-peroxidase (PAP) and avidin biotin-peroxidase complex (ABC) immunohistochemical methods, *Mycoplasma gallinarum* and *M gallinaceum* antigens were demonstrated in ethanol-fixed paraffin-embedded oviduct sections from hens the eggs from which showed suboptimal hatchability. Specific immunoperoxidase staining was detected at the mucosa in the magnum portion of the oviduct. Optimal staining was achieved by applying the ABC method, though both IIP and PAP methods can also be used for diagnosis. Isolation and identification techniques gave similar results for the species of avian mycoplasmas involved.

THERE are many species of mycoplasmas of poultry most of which are not pathogenic. However, infection with those that are pathogenic such as *Mycoplasma gallisepticum* and *M iowae*, has an important economic role due to the decrease in both egg production and hatchability (Rathore et al 1978, Stipkovits 1979).

Laboratory diagnosis of animal mycoplasma infections is generally based on the isolation of mycoplasmas from diseased tissues and the subsequent identification of the species involved (Gourlay 1981). Fluorescent antibody (FA) (Del Giudice et al 1967, Rathore et al 1978) and growth inhibition (GI) (Clyde 1964) tests have been widely used for the identification of those mycoplasmas that can form colonies easily (Imada et al 1987). However, it has been shown recently that mycoplasma identification, performed on fresh colonies by the indirect immunoperoxidase method, is as specific as that provided by GI tests (Imada et al 1987).

Immunohistological techniques, which are claimed to be highly sensitive, have been widely used for the rapid diagnosis of various bacterial (Hill 1978, Finlayson et al 1985, Poveda et al 1986) and viral (Fernandez et al 1989a, 1989b) infections on fixed samples.

This work was aimed to demonstrate immunohistologically and to identify specifically *M gallinarum* and *M gallinaceum* in infected alcohol-fixed paraffin-embedded oviducts from which those agents had been previously isolated, by means of three different immunohistochemical methods: indirect immunoperoxidase, peroxidase anti-peroxidase and avidin biotin peroxidase complex.

Materials and methods

Samples, tissue processing, and histochemical staining

Oviduct samples were collected from nine hens from a flock showing decreased hatchability and death of embryos. No agents or factors other than mycoplasma appeared to be involved, as demonstrated by routine microbiological and field studies. The nine hens were killed and the oviducts removed, sampled for microbiological studies by swabbing from the isthmus and magnum portions, and fixed in 96 per cent ethanol. Fixed tissues from all hens were embedded in paraffin wax by the method of Sainte-Marie (Sainte-Marie 1962), and 4 to 5 μm sections mounted with cromaleum-gelatine on to slides which were kept at 4°C until use.

The routine histochemical techniques that were used were haematoxylin and eosin, periodic acid Schiff (PAS) and red carmine (Best carmine).

Mycoplasma isolation

Oviduct samples were inoculated into 2 ml of modified liquid FM4 medium (Poveda et al 1990). After two to seven days of incubation at 37°C, they were streaked on to solid media which were incubated for seven days at 37°C in a moist atmosphere. Single colonies from each sample were cloned using standard techniques described by the Subcommittee on the Taxonomy of the Mollicutes (Subcommittee on the Taxonomy of Mollicutes 1979).

Biochemical and serological tests

The biochemical characteristics of isolates were determined according to the method of Aluotto et al (1970). The following tests were applied: growth in mycoplasma broth and agar medium without serum, sensitivity to digitonin, hydrolysis of urea, fermentation of glucose, hydrolysis of arginine, phosphatase activity, film and spots production, and tellurite and tetrazolium reduction in aerobic and anaerobic conditions. To identify the mycoplasma isolated, the GI test was applied, using filter paper discs impregnated with the antisera.

Each antiserum (see below) was tested for immunoreactivity and specificity with the homologous mycoplasma strain as well as with the other strains of avian mycoplasma using the indirect epi-immunofluorescence test on colonies grown on agar blocks which had been cut out from an agar plate. In addition, non-immune rabbit serum was reacted with each strain of avian mycoplasma as a negative control. Serum dilutions of 1/50, 1/200 and 1/500 in phosphate buffered saline (PBS) pH 7·2 were applied to agar blocks. As second antibody, IgG (Fc and Fab) of goat anti-rabbit serum (Chemicon International) conjugated with fluorescein isothiocyanate (FITC) was used diluted 1:20 in PBS. After treatment, the colonies were observed under the fluorescent microscope (Leitz).

Production of antisera

Antisera to the type strains of 13 species of avian mycoplasmas were produced in rabbits. These strains, kindly supplied by Dr E. A. Freundt (FAO/WHO Collaborating Centre for Animal Mycoplasmas), were as follows: *M anatis* (strain 1340), *M columbinasale* (694), *M columbinum* (MMP-1), *M columborale* (MMP-4), *M gallinaceum* (DD), *M gallinarum* (PG 16), *M gallisepticum* (PG 31), *M gallopavonis* (WR1), *M iners* (PG30), *M iowae* (695), *M meleagridis* (17529), *M pullorum* (CKK), and *M synoviae* (WVU 1853).

The reference strains were grown in modified FM4 medium (Poveda et al 1990) without thallium acetate, and supplemented with glucose (1 per cent) for those mycoplasmas fermenting glucose, and 0·2 per cent arginine for the arginine-hydrolysing mycoplasmas.

The modified immunising method of Senterfit (1983) was used in the following manner: on the first and 21st day, the animals (two rabbits for each species of avian mycoplasma) received four 0·5 ml intramuscular and one 0·2 ml intradermal dose of the antigen homogenised with incomplete Freund's adjuvant. The specificity of the antisera, which has been previously reported (Poveda et al 1990), was tested by the GI test (Clyde 1964).

Immunohistochemical study

Three different immunohistological methods were used: (i) indirect immunoperoxidase (IIP); (ii) peroxidase anti-peroxidase (PAP); (iii) avidin biotin-peroxidase complex (ABC). Antisera against *M gallinarum* and *M gallinaceum* strains were first tested on positive control material (ethanol-fixed paraffin-embedded oviduct tissue sections from hens 2 and 6) by each method to establish their optimal dilution (that giving the highest specific staining with the lowest background staining). From the oviduct of each of these hens *M gallinarum* was recovered and from hen 6, *M gallinaceum* was isolated. Optimal dilutions of both sera were found to be identical: 1/50 by the IIP method and 1/80 by both the PAP and the ABC methods. Afterwards, antisera to *M gallinarum* or *M gallinaceum* were applied to tissue sections of the remaining oviduct samples (hens 1, 3, 4, 5, 7, 8 and 9) and antisera against *M anatis, M columbinasale, M columbinum, M columborale, M gallisepticum, M gallopavonis, M pullorum, M synoviae, M iners, M meleagridis* and *M iowae* were similarly applied to tissue sections from all oviducts collected (hens 1 to 9 inclusive) by each method. Phosphate buffered serum (PBS) at pH 7·2 was used as the rinsing agent, while PBS-ovalbumin 1 per cent (w v^{-1}) (Sigma) (PBS-OVA) was used to dilute antisera. All incubations of tissue sections were performed in a moistened environment.

Each immunohistochemical method was applied to ethanol-fixed paraffin embedded oviduct tissue sections as follows.

IIP. This method was performed as previously described (Fernandez et al 1989b). Non-immune goat serum (DAKO) was diluted 1/30, while all specific antisera and the peroxidase-labelled goat anti-rabbit IgG serum (DAKO) were diluted 1/50. The enzyme was developed with 0·1 per cent 3,3′ diaminobenzidine tetrahydrochloride (Sigma) in 0·05 M Tris/HCl buffer pH 7·6 with 0·02 per cent hydrogen peroxide for 5 minutes.

PAP. This method was performed as described by Hill (1978) but modified by incubation of reactants for 10 minutes at room temperature with PBS-OVA after every rinse to reduce the background non-specific staining. Non-immune swine serum and swine anti-rabbit IgG antibody (DAKO) were diluted 1/30 and 1/50, respectively, while the rabbit peroxidase anti-peroxidase complex (DAKO) was diluted 1/100. The enzyme was developed as in the IIP method.

ABC. The method of Hsu et al (1981) was carried out following the instructions of the kit supplied by Vector Laboratories (Burlingame, California 94010) for rabbit immunoglobulins (PK-4001), to which was

TABLE 1: Immunohistochemical results obtained in ethanol-fixed paraffin-embedded oviduct samples

Sera anti-mycoplasma	Immunohistochemical techniques IIP	PAP	ABC	Number of hens*
M anatis	–	–	–	
M columbinasale	–	–	–	
M columbinum	–	–	–	
M columborale	–	–	–	
M gallinaceum	+/bg	++/bg	++	1
M gallinarum	+/bg	++/bg	++	8
M gallisepticum	–	–	–	
M gallopavonis	–	–	–	
M iners	–	–	–	
M iowae	–	–	–	
M meleagridis	–	–	–	
M pullorum	–	–	–	
M synoviae	–	–	–	
Normal rabbit serum	–/bg	–/bg	–	
Other negative controls	–	–	–	

+ Positive reaction, ++ More differentiated reaction
bg Unspecific background staining
* *M gallinarum* and *M gallinaceum* antigens were detected in the oviduct of one hen

added the PBS-OVA incubation step as with the other immunoenzymatic methods.

As negative controls for these methods the following were used:

(i) The substitution of the primary antiserum by non-immune rabbit serum diluted in PBS as the primary reactant (1:50 for IIP and 1:80 for PAP and ABC), and absorbed primary antiserum (after incubation with the antigen overnight at 4°C) diluted as the primary reactant (for *M gallinarum* only).

(ii) The application of the specific primary antisera to sections of oviducts of uninfected hens (negative isolation of avian mycoplasma species) from apparently uninfected flocks.

Results

Microbiological results

Antisera against *M gallinarum* and *M gallinaceum*, as well as all the other antisera, were highly specific, reacting only with the colonies of the homologous species.

Nine mycoplasma isolates were obtained from the oviducts sampled: from each of eight hens *M gallinarum* was recovered and from one *M gallinaceum* was recovered in addition. Three of the former isolates adsorbed guinea pig erythrocytes, a feature which may indicate a pathogenic potential (Sobeslavsky et al 1968). Oviduct samples from hen 7 were negative.

Histopathological results

Pathological changes were exclusively found at the magnum portion of the oviduct in all the birds studied. The mucosa of the magnum presented a diffuse infiltration of lymphocytes and plasma cells distributed among the tubular glands and at the sub-epithelial level, where plasma cells predominated.

The submucosa and muscular layers of the magnum also contained hyperplastic lymphoid tissue organised as germinal centres around lymphatic and venous vessels.

PAS staining of the magnum revealed the presence of mucins in some 90 per cent of the surface epithelial cells of the mucosa, which appeared large and rounded with basal nuclei. PAS negative, ciliated cells were scanty. Red carmine staining was also positive at that level, indicating the metabolic activity of the mucosa.

Immunohistochemical study

The magnum portion of ethanol-fixed paraffin-embedded oviduct samples from hens 1 to 9 (except 7) showed immunoreactive cells to *M gallinarum* with the three immunoenzymatic techniques (Table 1).

The positive reaction was found in both goblet and ciliated cells of the mucosa, which appeared isolated or, more frequently, in groups of two or three cells scattered among several negative ones (Fig 1). The immunoreactive material was concentrated at the surface of both types of cells (Fig 2, arrows) and also distributed throughout the cytoplasm of mucous cells (Fig 2 arrowhead).

None of the ethanol-fixed paraffin-embedded oviduct samples were immunoreactive to any of the other antisera used, except for samples from hen 6, which showed a positive reaction with *M gallinaceum* antisera, also at the level of the magnum. The distribution and localisation of immunoreactivity were similar to that for *M gallinarum*.

The comparative analysis of the results obtained by each method on oviduct tissue sections using the anti-*M gallinarum* sera revealed that the immunostaining obtained with the IIP method was the least satisfactory of all because of the non-specific staining of tubular glands of the mucosa, which tended to obscure the specific reaction (Fig 3). Further dilution of specific primaries from 1:50 to 1:80 eluted the specific immunoreaction without improving the deep background staining of these glands. The non-specific background staining observed with the specific antiserum was also present in those samples treated with normal rabbit serum diluted either 1:50 or 1:80 (Table 1). The PAP and ABC immunoreactivity was much clearer than with IIP, as the non-specific staining of the background was faint (PAP) or even

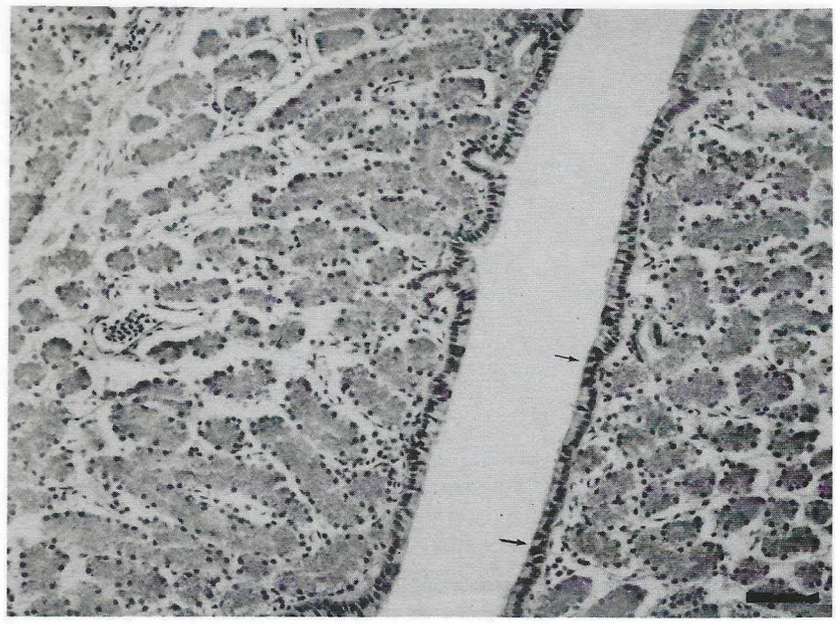

FIG 1: Immunoreactive cells to *M gallinarum* at the superficial epithelial layer of the mucosa (arrows) scattered among several negative cells. ABC method. Bar: 100 μm

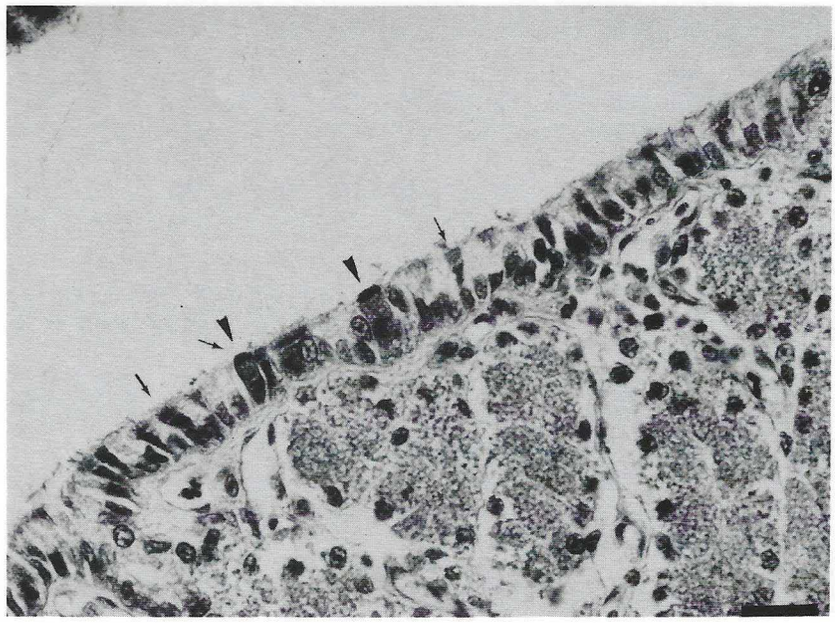

FIG 2: Immunoreactive material to *M gallinarum* appears at the surface of both mucous and ciliated cells (arrows) and also distributed throughout the cytoplasm of the former (arrowhead). ABC method. Bar: 20 μm

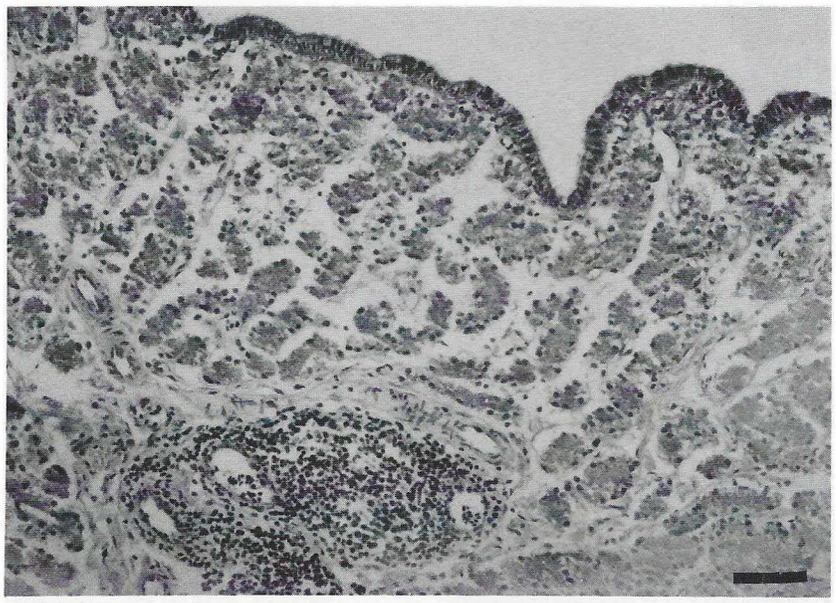

FIG 3: Immunoreaction obtained with *M gallinarum* antiserum. Note the deep non-specific staining of the tubular glands of the mucosa. Hyperplastic lymphoid tissue located in the submucosa appears at the bottom. IIP method. Bar: 100 μm

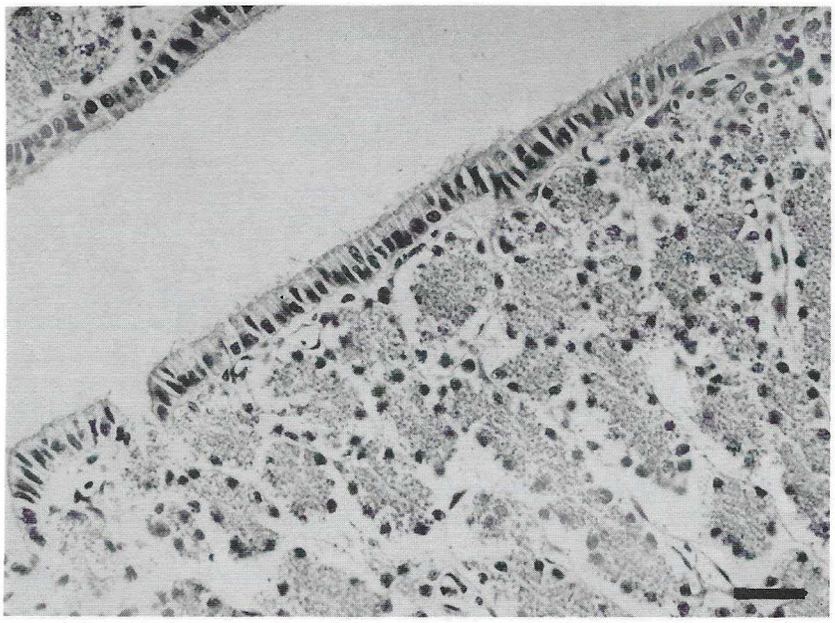

FIG 4: Negative control using non-immune rabbit serum as the primary reactant. Note the absence of reaction not only at the superficial layer of the mucosa but in the tubular glands also. This picture has been taken from a section adjacent to that shown in Fig 2. ABC method. Bar: 50 μm

absent (ABC) (Fig 4). No differences were noted in the numbers of immunoreactive cells detected by each method. However, immunoreactive material, located exclusively at the surface of the cells, was more frequent in ABC treated sections.

Tissue samples from hens 1 to 9, inclusive, were consistently negative with all three immunohistochemical methods when the primary antisera were substituted by non-immune rabbit serum. Equally, oviduct tissue samples from hen 7 were unreactive when incubated with any of the nine anti-mycoplasma sera used.

Discussion

Immunohistological techniques are reliable methods for the demonstration of infectious agents in histological sections of fixed and paraffin-embedded samples (Hill 1978, Finlayson et al 1985, Lutzky et al 1986, Poveda et al 1986, Fernandez et al 1989a, 1989b). The application of three of these techniques (IIP, PAP and ABC) to samples obtained from a natural mycoplasma infection of hen oviducts where the participation of either management problems or infectious agents other than avian mycoplasma species would appear to be unlikely, has proved to be very specific and advantageous. Antisera raised in rabbits in our laboratory were highly specific, as demonstrated by both GI and IIF serological tests (Poveda et al 1990). The specificity of antisera raised in rabbits to each species of mycoplasma had been previously reported (Imada et al 1987, Bradley et al 1988). This is an important advantage because antisera production is simple. Moreover, there was an exact correlation between the species of mycoplasmas identified by microbiological and immunohistochemical methods (*M gallinarum* and *M gallinaceum*), and antisera against these two species identified did not show cross reactions either between each other or with any of the other mycoplasma strains.

M gallinarum, which has been the only species of avian mycoplasmas demonstrated in all but one (hen 6) of our oviduct samples from hens with reproductive problems, is currently thought to be non-pathogenic. However, Kleven et al (1978) were able to induce an experimental air sacculitis in broilers after the inoculation of *M gallinarum* combined with Newcastle disease virus and infectious bronchitis virus. Immunohistochemical techniques allow the in situ demonstration of infecting microorganisms and, correspondingly, the correlation of histopathological findings with their exact location in tissues. In this study, a slight inflammatory infiltrate was found only at those levels where mycoplasmas were demonstrated immunohistochemically. These facts obviate cloning problems, as those mycoplasmas causing tissue damage can be easily identified, and open a new field in determining the pathogenicity of avian mycoplasmas. These techniques (IIP, PAP and ABC) are faster and cheaper than isolation and identification methods: a definite and specific diagnosis can be delivered within 48 to 72 hours of sampling, and all reagents needed to perform them, other than specific primary antisera, are widely available commercially. Moreover, samples can be submitted to the laboratory in the fixative of choice (96 per cent ethanol), avoiding their contamination. Though some authors have reported the immunohistochemical demonstration of *M pulmonis* in formaldehyde-fixed samples of mouse lung (Lutzky et al 1986). This fixative was not tried because the present authors think that protein-precipitating fixatives are the most suitable for the immunohistochemical identification of mycoplasmas as well as other infectious and non-infectious agents (Sainte-Marie 1962, Hill 1978, Polak and Van Noorden 1987, Fernandez et al 1989a,b), avoiding the enzymic digestion of tissues needed with aldehyde fixatives (Vandevelde et al 1983). While IIP was faster than the PAP and ABC methods, the latter, and specially the ABC method, rendered results of higher quality, a fact widely reported in several studies (Hsu et al 1981, Polak and Van Noorden 1987).

Acknowledgement

The critical comments of Dr R. L. Reece are greatly appreciated.

References

ALUOTTO, B. B., WITTER, R. G., WILLIAMS, C. O. & FABER, J. E. (1970) *International Journal of Systematic Bacteriology* **20**, 35–38

BRADLEY, L. D., SNYDER, D. B. & VAN DENSSEN, A. (1988) *American Journal of Veterinary Research* **49**, 511

CLYDE, W. A., Jr (1964) *Journal of Immunology* **92**, 958–965

DEL GIUDICE, R. N., ROBILLARD, N. F. & CARRSKI, T. R. (1967) *Journal of Bacteriology* **93**, 1205–1209

FERNÁNDEZ, A., HEWICKER, M., TRAUTWEIN, G., PHOLENZ, J. & LIESS, B. (1989a) *Veterinary Pathology* **26**, 26–32

FERNÁNDEZ, A., MARTÍN DE LAS MULAS, J., SIERRA, M. A., CARRANZA, J. & JOVER, A. (1989b) *Deutsche Tierärztliche Wochenschrift* **96**, 192–194

FINLAYSON, J., BUXTON, D., ANDERSON, I. E. & DONALD, K. M. (1985) *Journal of Clinical Pathology* **38**, 712–714

GOURLAY, R. N. (1981) *Israel Journal of Medical Science* **17**, 654–655

HILL, A. C. (1978) *Journal of Infectious Diseases* **137**, 152–154

HSU, S., RAINE, L. & FANGER, H. (1981) *Journal of Histochemistry and Cytochemistry* **29**, 577–580

IMADA, Y., UCHIDA, I. & HASHIMOTO, K. (1987) *Journal of Clinical Microbiology* **25**, 17–21

KLEVEN, S. H., EIDSON, C. S. & FLETCHER, O. J. (1978) *Avian Diseases* **22**, 707–716

LUTZKY, I., LIVNI, N. & MOR, N. (1986) *Pathology* **18**, 390–392

POLAK, J. M. & VAN NOORDEN, S. (1987) An Introduction to Immunocytochemistry: Current Techniques and Problems. Revised edn (Microscopy Handbook II). Oxford, Oxford University Press, Royal Microscopical Society. pp 14–35

POVEDA, J. B., FERNÁNDEZ, A., CARRANZA, J., HERMOSO, M. & PEREA, J. A. (1986) *Avian Pathology* **15**, 797–802

POVEDA, J. B., CARRANZA, J., MIRANDA, A., GARRIDO, A., HERMOSO, M., FERNÁNDEZ, A. & DOMENECH, J. (1990) *Avian Pathology* (In press)

RATHORE, B. S., MOHANTY, G. C. & RAJYA, B. S. (1978) *Indian Journal of Veterinary Pathology* **3**, 15–17

SAINTE-MARIE, G. (1962) *Journal of Histochemistry and Cytochemistry* **10**, 250–256

SENTERFIT, L. B. (1983) Methods in Mycoplasmology, vol 1. Eds J. G. Tully and S. Razin. New York, Academic Press. pp 401–404

SOBESLAVSKY, O., PRESCOTT, B. & CHANOCK, R. M. (1968) *Journal of Bacteriology* **96**, 695–705

STIPKOVITS, L. (1979) *Zentralblatt für Bakteriologie und Hygiene I*, Abt Orig **A245**, 171–183

SUBCOMMITTEE ON THE TAXONOMY OF MOLLICUTES (1979) *International Journal of Systematic Bacteriology* **22**, 172–180

VANDEVELDE, M., HUGI, E. & ISTERA, A. (1983) *Research in Veterinary Science* **34**, 193–198

Received January 22, 1990
Accepted May 17, 1990