

First case reported of bronchoconstriction in feline aelurostrongylosis by using barometric whole-body plethysmography

- GARCÍA-GUASCH L. Hospital Veterinari Molins, Pol. Ind. Molí dels Frares
- MANUBENS J. Hospital Veterinari Molins, Pol. Ind. Molí dels Frares
- LAPORTA M. Hospital Veterinari Molins, Pol. Ind. Molí dels Frares
- CARRETÓN E. Internal Medicine, Faculty of Veterinary Medicine, Research Institute of Biomedical and Health Sciences (IUIBS), University of Las Palmas de Gran Canaria
- MONTOYA-ALONSO J. Internal Medicine, Faculty of Veterinary Medicine, Research Institute of Biomedical and Health Sciences (IUIBS), University of Las Palmas de Gran Canaria

<http://dx.doi.org/10.12681/jhvms.15615>

Copyright © 2018 L GARCÍA-GUASCH, J MANUBENS, M LAPORTA, E CARRETÓN, JA MONTOYA-ALONSO



To cite this article:

GARCÍA-GUASCH, L., MANUBENS, J., LAPORTA, M., CARRETÓN, E., & MONTOYA-ALONSO, J. (2018). First case reported of bronchoconstriction in feline aelurostrongylosis by using barometric whole-body plethysmography. *Journal of the Hellenic Veterinary Medical Society*, 66(2), 101-105. doi:<http://dx.doi.org/10.12681/jhvms.15615>



First case reported of bronchoconstriction in feline aelurostrongylosis by using barometric whole-body plethysmography

García-Guasch L^{1*}, Manubens J¹, Laporta M¹, Carretón E², Montoya-Alonso J.A.²

¹ Hospital Veterinari Molins, Pol. Ind. Molí dels Frares, B-27, 08620 Sant Vicens dels Horts (Barcelona), Spain.

² Internal Medicine, Faculty of Veterinary Medicine, Research Institute of Biomedical and Health Sciences (IUIBS), University of Las Palmas de Gran Canaria, 35413 Arucas (Las Palmas), Spain

ABSTRACT. Symptomatic cats infected by *Aelurostrongylus abstrusus* show non-specific and respiratory clinical signs, often misdiagnosed as other diseases more prevalent among feline population, such as allergic respiratory disease or heartworm associated respiratory disease (HARD). Clinical signs are due to the pulmonary inflammatory response caused by the eggs shed by the adult females and the migration of the first-stage larvae up the bronchial tree. Barometric whole-body plethysmography (BWBP) is a non-invasive pulmonary function test that allows a dynamic study of breathing patterns by placing the patient within an unrestrained Plexiglas chamber. This is the first report that determines the degree of bronchoconstriction caused by *A. abstrusus* infection in a cat by using BWBP, showing an increase of baseline measurements of bronchoconstriction indexes (Enhanced pause and Pause) in response to severe bronchial reactivity, a consequence of the airway inflammation caused by the presence of *A. abstrusus*.

Keywords: *Aelurostrongylus abstrusus*, bronchoconstriction, feline bronchial disease, plethysmography

INTRODUCTION

Aelurostrongylus abstrusus (Nematoda, Strongylida) lungworm is a parasite which infects domestic cats in numerous parts of the world. In Europe, infections by *A. abstrusus* have been described in almost all European countries (Traversa et al., 2010). Furthermore, some reports indicate an expansion in the geographical range of the disease and an awareness that infection in cats may be much more common than previously thought (Traversa and Guglielmini, 2008; Taubert et al., 2009; Traversa et al., 2010). It is currently considered to be an emerging

disease, probably due to climate changes, with global warming leading to the spread of a variety of definitive, intermediate and paratenic hosts, the enhanced awareness of veterinary practitioners and improved diagnostic tools or surveillance (Jobin, 1999; Root et al., 2003; Traversa and Guglielmini, 2008).

The usefulness of pulmonary function tests (PFT) has been described in dogs and cats, including evaluation of respiratory patterns (McKiernan et al., 1993; Dye and Costa, 2004; Bach et al., 2007), bronchial reactivity (Hoffman et al., 1999; Kirschvink et al., 2007; García-Guasch et al., 2012, 2013), as well as the response to bronchoconstrictive and bronchodi-

Corresponding author: Hospital Veterinari Molins,
Pol. Ind. Molí dels Frares, B-27
08620 Sant Vicens dels Horts (Barcelona), Spain.
E-mail: laingarcia@gmail.com

Date of initial submission: 26.03.2014
Date of revised submission: 18.06.2014
Date of acceptance: 27.06.2014

latory agents (Kirschvink et al., 2005; Leemans et al., 2009). Barometric whole-body plethysmography (BWBP) is a non-invasive PFT that allows a dynamic study of breathing patterns by placing the patient in an unrestrained Plexiglas chamber (Figure 1). Using specialized software, a unitless variable called Enhanced pause (Penh), may be calculated as an index of bronchoconstriction. Penh has been shown to correlate with airway resistance, bronchoconstriction and bronchodilation, and airway inflammation (Kirschvink et al., 2006; Hirt et al., 2008). As no restraint is required, the procedure is of limited or no stress to the patient. In cats, BWBP is particularly attractive for the study of feline bronchial disease and heartworm associated respiratory disease (HARD) (García-Guasch et al., 2012, 2013). The aim of this case report is to evidence bronchoconstriction associated with *A. abstrusus* infection through the analysis of baseline respiratory function variables obtained by BWBP.

CASE DESCRIPTION

An outdoor male European Shorthair cat aged 1 year from Barcelona (Spain) was presented to the Cardiology and Respiratory Service of the Hospital Veterinari Molins with a 3 months history of moderate respiratory distress and coughing. The cat had been previously treated with corticoids and antibiotics showing no adequate response. It had not been dewormed in the previous 3 months and had no exposure to passive smoke inhalation or other inhaled bronchoconstrictive agents. The findings on clinical examination were intermittent coughing, dyspnoea and tachypnea. Respiratory rate was 112 breaths/min and heart rate was 190 beats/min. Auscultation of the thorax revealed moderately increased respiratory sounds with end-inspiratory crackles. Thoracic radiographs showed severe broncho-alveolar infiltrates in the caudodorsal lung fields. Laboratory findings were negative for feline leukaemia, feline immunodeficiency virus as well as heartworm antigens and antibodies. Blood count and serum biochemistry were within normal ranges.

BWBP was performed as previously described by



Figure 1. Cat placed into a plethysmography chamber connected to commercial software, used to analyse the respiratory patterns. The chamber is placed in a quiet room with calibrated temperature and humidity, and cats are acclimated to the chamber for 5 minutes after which data are recorded for a period of 12 minutes.

García-Guasch et al. (2012). Pressure signals were recorded to obtain values for respiratory rate [RR], inspiratory and expiratory time [Ti and Te], tidal volume [TV], minute ventilation [MV], and bronchoconstriction indexes Pause [PAU] and Enhanced pause [Penh]. Comparing results with the reference values obtained from healthy cats as previously reported by the same authors (García-Guasch et al., 2012), bronchoconstriction indexes were found to be significantly increased in this cat (Table 1).

Samples of bronchoalveolar lavage (BAL) fluid were collected as previously described by Lacorcía et al. (2009). Examination of BAL fluid resulted in detection of larvae of *A. abstrusus*. Features used to identify larvae were a length of 360 to 400 μm , the lack of a sheath, the presence of a small buccal capsule, a coiled or s-shaped appearance, and a subterminal spine on the tail (Lacorcía et al., 2009; Traversa et al., 2010).

Fenbendazole was given orally at 50 mg/kg daily 15 consecutive days. Inhaled salbutamol (100 μgr TID) during 15 consecutive days and inhaled fluticasone (250 μgr BID) during 7 consecutive days were prescribed to improve bronchoconstriction. After two weeks of treatment, a clinical improvement was noted, with remission of the cough, dys-

pnoea and tachypnea. Follow-up BWBP revealed a clear reduction in bronchoconstriction indexes compared with previous results (PAU=0,547±0,299 vs 1,096±0,400; Penh=0,311±0,208 vs 1,126±0,593). BAL was repeated one week after the end of the treatment (day 21) and no larvae were found. Faecal samples were collected during three consecutive days and immediately subjected to macroscopic and microscopic examination for first-stage *A. abstrusus* larvae using Baermann technique, as previously described (Euzeby, 1981). No larvae were detected in any faecal sample. Monthly spot-on formulation containing imidacloprid 10% and moxidectin 1% was prescribed as preventive treatment.

DISCUSSION

The clinical signs of *A. abstrusus* infection are due to the inflammatory response caused by the eggs shed by the adult females and the migration of the first-stage larvae up the bronchial tree causing progressive disruption of the vascular endothelium resulting in vacuolation and later proliferation of the endothelial cells in the pulmonary alveoli, bronchioles and local arteries (Traversa et al., 2010). Those signs are generally non-specific and include coughing, tachypnea,

tachycardia, weight loss, dyspnoea, poor condition, sneezing, nasal discharge and open-mouthed abdominal breathing. Due to the positive response to corticotherapy, feline aelurostrongylosis may be misdiagnosed as allergic respiratory disease.

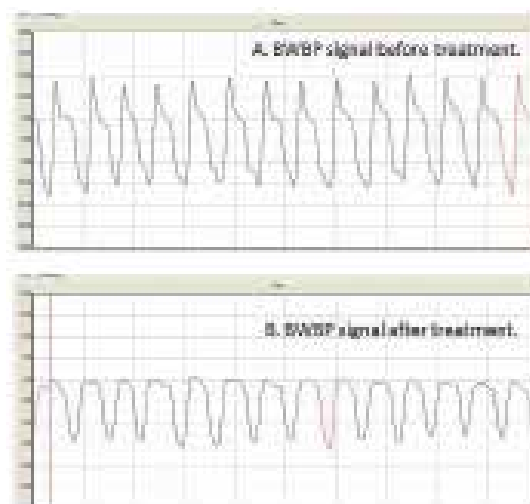


Figure 2. A. Barometric whole-body plethysmography (BWBP) signal from a cat with bronchoconstriction due to feline aelurostrongylosis. Note the marked early peak expiratory flow (PEF). B. BWBP signal from the same cat after two weeks of treatment. Note that the marked early PEF has disappeared.

Table 1. Values of analyzed BWBP variables obtained in healthy cats and in a cat with *A. abstrusus* infection prior to and post treatment. [RR: respiratory rate; Ti and Te: inspiratory and expiratory times; TV: tidal volume; MV: minute ventilation (TV x RR); RT: relaxation time; PIF: peak inspiratory flow; PEF: peak expiratory flow; PAU: pause [(Te-RT)/RT]; Penh: enhanced pause [(PEF/PIF)-PAU].

	<i>A. abstrusus</i> infected cat before treatment	<i>A. abstrusus</i> infected cat after treatment	Healthy cats (n=25) (García-Guasch et al., 2012)
	Mean ± SD	Mean ± SD	Mean ± SD
RR (rpm)	112±19	98±12	60±24
Ti (ms)	0,241±0,055	0,252±0,025	0,515±0,165
Te (ms)	0,311±0,064	0,370±0,055	0,837±0,350
TV (mL)	31,04±10,86	16,73±3,41	32,32±10,75
MV (mL)	3336,84±563,56	1614,45±267,37	1590,08±399,95
RT (ms)	0,152±0,038	0,245±0,046	0,553±0,226
PIF (mL/s)	189,94±25,11	103,03±12,94	100,56±23,85
PEF (mL/s)	187,83±40,47	55,36±6,07	68,00±16,76
PAU	1,096±0,400	0,547±0,299	0,610±0,143
Penh	1,126±0,593	0,311±0,208	0,460±0,123

Histopathologic pulmonary changes are eosinophilic and neutrophilic infiltrates in the larger and smaller bronchi as well as in the bronchioles, and extensive multifocal granulomatous inflammation in the peribronchial tissue (Dirven et al., 2012). Furthermore, *A. abstrusus* infection may cause prolonged vasoconstriction mediated by mast cells and histamine release, triggering increased pulmonary vascular resistance and producing pulmonary hypertension (Dirven et al., 2012). Since the bronchial mucosa is infiltrated by inflammatory cells due to the presence of *A. abstrusus*, by using the BWBP, it is possible to determine the degree of broncho-reactivity caused by the worms in the symptomatic infected cat. The Penh and PAU variables assess the degree of resistance to the air flow in the airways. It has been demonstrated that the increase in Penh value is influenced by the degree of bronchoconstriction. For this reason Penh value is a valid indicator of bronchoconstriction state (Hamelmann et al., 1997).

Bronchial alterations show a modified BWBP pseudoflow signal, by generating a marked peak in the early expiratory phase of the breathing cycle as shown in Figure 2A. This peak will increase as the bronchoconstriction degree increases. Once the patient was successfully treated, BWBP signal normalized and the early expiratory peak fell (Figure 2B).

To the authors' knowledge, this is the first report that evidences, through the use of a PFT, a severe bronchoconstriction in response to an airway inflammation produced by feline aelurostrongylosis. This being similar to that previously reported in cats infected with *D. immitis* (García-Guasch et al., 2012, 2013). Feline aelurostrongylosis may be misdiagnosed as an allergic respiratory disease due to its positive response to the administration of corticosteroids

and bronchodilators. Furthermore, similar respiratory signs are found in feline HARD (Simón et al., 2012), therefore is very likely to misdiagnose *A. abstrusus* as *D. immitis* (Traversa et al., 2008). Therefore, due to the emerging nature of the disease *A. abstrusus* infection should be included within the differential diagnosis of cats with cardio-respiratory clinical signs (Tril and Reinero, 2014).

In this disease, clinical signs are mainly secondary to the inflammation present in the larger and smaller bronchi as well as in the bronchioles. For this reason, treatment must be focused on controlling airway inflammation and eliminating the etiologic agent. To this end, inhaled corticoids and bronchodilators were prescribed, once the bronchoconstriction was confirmed by BWBP. Finally, it has been demonstrated that, after the elimination of the *A. abstrusus* infection, PAU and Penh returned to ranges similar to healthy cats as shown in Table 1.

CONCLUDING REMARKS

This report supports the usefulness of the BWBP as a clinical tool in the evaluation of cats with respiratory disease associated with *A. abstrusus* infection and as a method of short and long-term therapeutical monitoring. However, more studies in cats infected by *A. abstrusus* should be carried out together with histopathological studies to define the nature of the lesions responsible for the bronchial alteration.

CONFLICT OF INTEREST STATEMENT

None of the authors of this paper has a financial or personal relationship with other people or organizations that could inappropriately influence or bias the content of the paper. ■

REFERENCES

- Bach JF, Rozansky EA, Bedenice D, Chan DL, Freeman LM, Lofgren JL, Oura TJ, Hoffman AM (2007) Association of expiratory airway dysfunction with marked obesity in healthy adult dogs. *Am J Vet Res* 68: 670-675.
- Dirven M, Szatmári V, Van Den Ingh T, Nijssse R (2012) Reversible pulmonary hypertension associated with lungworm infection in a young cat. *J Vet Cardiol* 14: 465-474.
- Dye JA, Costa DL (2004) Pulmonary mechanics. In: (ed: King LG) *Textbook of respiratory disease in dogs and cats*, Elsevier-Saunders, St. Louis, pp. 157-175.
- Euzeby J (1981) La coprologie chez les carnivores. In: (ed: Euzeby J) *Diagnostic experimental des helminthoses animales. Travaux pratiques d'helminthologie veterinaire, Livre 1, Informations Techniques des Services Vétérinaires, Paris, France*, pp. 195-214.
- García-Guasch L, Caro-Vadillo A, Manubens-Grau J, Carretón E, Morchón R, Simón F, Montoya-Alonso JA (2012) Evaluation of pulmonary function variables by using plethysmography in cats with respiratory disease associated to *Dirofilaria immitis*. *Vet Parasitol* 187: 254-258.
- García-Guasch L, Caro-Vadillo A, Manubens-Grau J, Carretón E, Morchón R, Simón F, Kramer LH, Montoya-Alonso JA (2013) Is *Wolbachia* participating in the bronchial reactivity of cats with heartworm associated respiratory disease?. *Vet Parasitol* 196: 130-135.
- Hamelmann E, Schwarze J, Takeda K, Oshiba A, Larsen GL, Irvin CG, Gelfand EW (1997) Non-invasive measurement of airway responsiveness in allergic mice using barometric plethysmography. *Am J Respir Crit Care Med* 156: 766-775.
- Hirt RA, Leinker S, Mosing M, Wiederstein I (2008) Comparison of barometric whole-body plethysmography and its derived parameter enhanced pause (Penh) with conventional respiratory mechanics in healthy Beagle dogs. *Vet J* 176: 232-239.
- Hoffman AM, Dhupa N, Cimetti L (1999) Airway reactivity measured by barometric whole-body plethysmography in healthy cats. *Am J Vet Res* 60: 1487-1492.
- Jobin W (1999) *Ecological Design and Health Impacts of Large Dams, Canals, and Irrigation Systems*, E&F.N, Spon, UK, London.
- Kirschvink N, Leemans J, Delvaux F, Snaps F, Clercx C, Gustin P (2005) Bronchodilators in bronchoscopy-induced airflow limitation in allergen-sensitized cats. *J Vet Intern Med* 19: 161-167.
- Kirschvink N, Leemans J, Delvaux F, Snaps F, Jaspert S, Evrard B, Delattre L, Cambier C, Clercx C, Gustin P (2006) Inhaled fluticasone reduces bronchial responsiveness and airway inflammation in cats with mild chronic bronchitis. *J Fel Med Surg* 8: 45-54.
- Kirschvink N, Leemans J, Delvaux F, Snaps F, Clercx C, Gustin P (2007) Functional, inflammatory and morphological characterization of a cat model of allergic airway inflammation. *Vet J* 174: 541-553.
- Lacorcia L, Gasser RB, Anderson GA, Beveeridge I (2009) Comparison of bronchoalveolar lavage fluid examination and other diagnostic techniques with the Baermann technique for detection of naturally occurring *Aelurostrongylus abstrusus* infection in cats. *J Am Vet Med Assoc* 235: 43-49.
- Leemans J, Kirschvink N, Bernaerts F, Clercx C, Cambier C, Gustin P (2009) A pilot study comparing the antispasmodic effects of inhaled salmeterol, salbutamol and ipratropium bromide using different aerosol devices on muscarinic bronchoconstriction in healthy cats. *Vet J* 180: 236-245.
- Mckiernan BC, Dye JA, Rozanski EA (1993) Tidal breathing flow-volume loops in healthy and bronchitic cats. *J Vet Intern Med* 7: 388-393.
- Naylor JR, Hamilton JM, Weatherley AJ (1984) Changes in the ultrastructure of feline pulmonary arteries following infection with the lungworm *Aelurostrongylus abstrusus*. *Br Vet J* 140: 181-190.
- Root TL, Price JT, Hall KR, Schneider SH, Rosenzweig C, Pounds JA (2003) Fingerprints of global warming on wild animals and plants. *Nature* 421: 57-60.
- Simón F, Siles-Lucas M, Morchón R, González-Miquel J, Mellado I, Carretón E, Montoya-Alonso JA (2012) Human and animal dirofilariosis: the emergence of a zoonotic mosaic. *Clin Microbiol Rev* 25: 507-544.
- Taubert A, Pantchev N, Vrhovec MG, Bauer C, Hermosilla C (2009) Lungworm infections (*Angiostrongylus vasorum*, *Crenosoma vulpis*, *Aelurostrongylus abstrusus*) in dogs and cats in Germany and Denmark in 2003-2007. *Vet Parasitol* 159: 175-180.
- Traversa D, Lia RP, Iorio R, Boari A, Paradies P, Capelli G, Avolio S, Otranto D (2008) Diagnosis and risk factors of *Aelurostrongylus abstrusus* (Nematoda, Strongylida) infection in cats from Italy. *Vet Parasitol* 153: 182-186.
- Traversa D, Guglielmini C (2008) Feline aelurostrongylosis and canine angiostrongylosis: a challenging diagnosis for two emerging verminous pneumonia infections. *Vet Parasitol* 157: 163-174.
- Traversa D, Di Cesare A, Conboy G (2010) Canine and feline cardiopulmonary parasitic nematodes in Europe: emerging and underestimated. *Paras Vect* 3: 62.
- Trzil JE, Reiner CR (2014) Update on feline asthma. *Vet Clin Small Anim* 44: 91-105.